

EDITORIAL BOARD

PATRON

Mr. Imbesat Shaukat

Hon'ble Managing Director, Mithila Minority Dental College & Hospital, Darbhanga
(Lalit Narayan Mithila University, Darbhanga)
Lifetime Senate Member, Lalit Narayan Mithila University, Darbhanga

ADVISORY BOARD

Prof. Dr. Arun Suresh Dodamani

Principal, Professor & Head Dept. of Public Health Dentistry,
A.C.P.M. Dental College, Dhule (Maharashtra)
(Maharashtra University Of Health Sciences, Nashik)

Prof Dr. Debashish Banerjee

Professor
Dept. of Conservative Dentistry and Endodontics
Hon'ble Member, Dental Council of India (New Delhi)

EDITOR IN CHIEF

Dr. A. Sudheer

Principal, Professor & Head,
Dept. of Prosthodontics and Crown & Bridge
Mithila Minority Dental College & Hospital, Darbhanga

EXECUTIVE EDITOR

Dr. Tauseef Fazal

Associate Professor,
Dept. of Oral & Maxillofacial Surgery,
MMDCH, Darbhanga

Dr. Puja Saha

Assistant Professor,
Dept of Orthodontics & Dentofacial
Orthopaedics, MMDCH, Darbhanga

Dr. Qayanaat Shaukat

Faculty
MMDCH, Darbhanga

Dr. Chetan Vinay Deshmukh

Assistant Professor,
Dept. of Public Health Dentistry,
Nair Hospital Dental College, Mumbai

ASSOCIATE EDITOR

Dr. K S Banga

Professor & Head, Dept. of
Conservative Dentistry &
Endodontics, Nair Hospital
Dental College, Mumbai,
Maharashtra University of
Health Sciences, Nashik

Dr. Ranadheer Eeravani

Professor & Head, Dept. of
Pedodontics & Preventive
Dentistry, MMDCH,
Darbhanga

Dr. Harendra Shahi

Professor, Dept. of
Prosthodontics and Crown &
Bridge, MMDCH, Darbhanga

Prof. Dr. Swapnil Bumb

Associate Professor, Dept. of
Public Health Dentistry,
A.C.P.M. Dental College,
Dhule (Maharashtra)
Maharashtra University of
Health Sciences, Nashik

Dr. Veerendra Kerudi

Assistant Professor, Dept of
Orthodontics & Dentofacial
Orthopaedics, ACPM Dental
College, Dhule

Dr. Anuj Bhardwaj

Professor, Dept. of
Conservative Dentistry &
Endodontics, College of
Dental Sciences and Hospital,
Indore

Dr. Reshma Hammanavar

Associate Professor, Dept. of
Oral & Maxillofacial Surgery,
ACPM Dental College, Dhule

Dr. Anand Rajapur

Professor, Dept. of
Prosthodontics and Crown &
Bridge, RIMS Dental College,
Imphal

Dr. Subhash Bhoyar

Principal, Professor & Head,
Oral & Maxillofacial Surgery,
Chhatrapatil Shahu Maharaj
Shikshan Sanstha's Dental
College & Hospital,
Aurangabad, Maharashtra
University of Health Sciences,
Nashik

Dr. Anjani Kumar Jha

HOD, Professor, Dept. of Oral
& Maxillofacial Surgery,
MMDCH, Darbhanga

Dr. Alka Kale

Principal, Professor & Head,
Oral Pathology, KLE
Viswanath Katti Institute of
Dental Sciences,
Belagaum(Karnataka)

Dr. Sonahita Agarwal

Professor, Dept. of
Orthodontics & Dentofacial
Orthopaedics, MMDCH,
Darbhanga

Dr. Amit Kumar

Professor, Dept. of
Conservative Dentistry &
Endodontics, MMDCH,
Darbhanga

Dr. Harpreet Singh Chhabra

Professor, Dept. of
Conservative Dentistry &
Endodontics, Sardar Patel Post
Graduate Institute of Dental &
Medical Sciences

Dr. Mehendi Hassan

Assistant Professor, Dept. of
Orthodontics & Dentofacial
Orthopaedics, MMDCH,
Darbhanga

प्रोफेसर सुरेन्द्र प्रताप सिंह
कुलपति
Prof. Surendra Pratap Singh
Vice-Chancellor



ललित नारायण मिथिला विश्वविद्यालय
LALIT NARAYAN MITHILA UNIVERSITY
कामेश्वरनगर, दरभंगा - 846004 बिहार
Kameshwaranagar, Darbhanga - 846004 Bihar

Ref. No.

Date

MESSAGE

I would like to begin with a hope and desire that all our healthcare providers are safe in this unexpected battle against COVID-19 pandemic which has gripped the world and has cost so much in life & resources.


First of all, I would like to congratulate the Chief and associated Editors, Advisory Board comprising of Professors from various distinguished institutions, other faculty members and contributors, patrons and our beloved students and researchers associated with the Journal of Oral and Dental Health. It gives me tremendous delight to see this journal bringing up yet another issue. I want to specially congratulate **Mithila Minority Dental College & Institution** for its brilliant effort and statesmanship for making the Journal of Oral and Dental Health the official publication of L.N. Mithila University, Darbhanga.

It gives me immense pleasure to see the Journal in widespread circulation and benefitting numerous researchers and academicians in their quest for scientific temper and knowledge. This Journal and its issues are greatly benefitting Dental professionals and practitioners associated with the field of Dentistry and its allied post-graduate branches, thereby providing an overall enlightenment.

Today, Dentistry has evolved much since its inception and humble beginnings. The skeletal and aesthetic treatment & satisfaction of a patient often involves an interdisciplinary approach. As such, the Journal of Oral Dental Health through its collection of brilliant researches from all across the country, Epidemiological studies and data presented in its various issues boost a lot of confidence in young surgeons and Dentists alike.

I would conclude by wishing lots of success to the Editorial and Advisory Board in its present and future endeavours.

Best wishes & regards,


Surendra Pratap Singh

MESSAGE FROM THE MANAGING DIRECTOR

—It is the supreme art of the teacher to awaken joy in creative expression and knowledge.

Albert Einstein

I am extremely happy and proud that a new issue of our esteemed Journal is being published. Our editorial team is continuously working hard to upgrade the quality of the publications. I am sure that these articles will be of extreme help to upgrade the knowledge of dental education.

Our faculties and post graduate students are getting an opportunity to publish their work which I am very happy about. And I came to know that even authors from many other Dental Colleges are contributing their articles. This I believe will be an excellent platform for sharing scientific thoughts.

With more and more original articles pouring in, I am sure that Journal of Oral & Dental Health will be one of the premium Journals in the field of Dentistry.

Wishing success and best wishes to the Editorial team.



Imbesat Shaukat

*Managing Director
Mithila Minority Dental College & Hospital,
Darbhanga, Bihar*

MESSAGE FROM THE EDITOR IN CHIEF

Dear Readers,

Authors of various articles are appreciated to be chosen for publication in "Journal of oral & dental health". However our priority of publication always remains towards innovative research work. Till date no concrete work has been done on prevention of spread of viral infection from patient to dental surgeon or vice versa.

So, scope is available for research & innovation. Hope authors take interest to go ahead with research on this aspect and bring shield of Protection.



Dr. Arunachalam Sudheer,
Principal, Professor & Head, Prosthodontics and Crown & Bridge
Editor in Chief
Journal of Oral & Dental Health

Mithila Minority Dental College & Hospital
Journal of Oral and Dental Health • Vol 8 • Issue 1 • 2023
Darbhanga (Bihar)

MESSAGE FROM THE ADVISORY BOARD

—*Research is the creation of new knowledge!*
- Neil Armstrong
Greetings to one & all!

It gives me immense pleasure to welcome all avid readers to this inaugural edition of the Journal of Oral and Dental Health. This Journal is an official publication of the Mithila Minority Dental College & Hospital, Darbhanga (Bihar) affiliated to the State run Lalit Narayan Mithila University, Darbhanga, Bihar State (India) established and administered by the State Govt. of Bihar State and holds abundant potential to provide a platform for budding research professionals in Dental Sciences across the country and the South East Asian region.

In today's era of constant need of advanced technologies in every discipline, it has become imperative for young professionals and academicians alike to keep themselves updated with the latest scientific innovations & break through. This is only possible through a constant review of scientific literature and adopting a temperament of scientific research.

Every scientific breakthrough has been made possible only by inculcating a scientific temperament which promotes scientific curiosity & research in individuals. Research is a constant and dynamic pursuit of an idea and developing into a hypothesis, testing it through various methodologies which finally culminates into publishing it through various platforms.

A publication signifies the efforts of various individuals associated with an idea and the results and thus a scientific journal is a worthy platform which helps in showcasing these efforts. This journal, a culmination of efforts from stalwarts of various disciplines, will definitely prove to be wonderful opportunity for academicians as well budding professionals

My gratitude to the Founder Chairman of Mithila Minority Dental College & Hospital and the leadership of this journal, the Chief Patron – Acharya Shaukat Khail for his invaluable guidance. I thank the Patron of the Journal as well as Managing Director of MMDCH Mr. Imbesat Shaukat for getting me on board with this wonderful initiative. I thank the Editor in Chief, Dr. Rohit Miglani and the rest of the Editorial Board for their support.

I also take this opportunity to invite faculties in various dental institutes, clinicians, students, etc. to contribute to this journal by sending in their scientific studies and help enhance the scientific content of our discipline of dentistry.

Lastly, I congratulate the authors of the articles of this inaugural edition for successful publication of research.



Thank You

Regards

DR. ARUN S. DODAMANI

Principal, Prof & Head,
Dept. of Public Health Dentistry,
A.C.P.M. Dental College, Dhule

Maharashtra University of Health Sciences, Nashik

Ex- Chairman Board of Studies
Ex-Academic Council Member
Ex-Faculty Member
First college to start PG in Public Health Dentistry at ACPMDC Dhule
PhD Guide
UG & PG Examiner

Executive Committee Member
Maharashtra State Dental Council

Lifetime Senate Member
Lalit Narayan Mithila University, Darbhanga, Bihar

Hon. Vice President
Indian Association of Public Health Dentistry

Hon. Gen. Secretary
Indian Association of Public Health Dentistry – Maharashtra Chapter

ORIGINAL ARTICLE

To Evaluate Extraoral (Kurt Thoma) Vs Intraoral (Vazirani Akinosi) Technique Of Mandibular Nerve Block In Mandibular Teeth Extraction

Dr. Anjani Kumar Jha, Dr. Prity Kumari, Dr. Tauseef Fazal, Dr. Ashish Kumar, Dr. Ashiq Hussan Ansari, Dr. Akash Ganguly

1

Evaluation To Evaluate The Efficacy of 4% Articaine Versus 2 % Lignocaine In Mandibular Third Molar Surgery

Dr. Anjani Kumar Jha, Dr. Anil Kumar, Dr. Tauseef Fazal, Dr. Ashish Kumar, Dr. Ashiq Hussan Ansari, Dr. Akash Ganguly, Dr. Madhukar Kumar

9

A Comparative Study on Cryogenically and Heat Treated Sodium Hypochlorite on The Fracture Resistance of Endodontically Treated Teeth: An In Vitro Study

Dr. Harpreet Singh Chhabra, Dr. Ikshita Deshwa, Dr. Sanjeev Kumar Srivastava, Dr. Kshiti Bhardwaj, Dr. Aditya Singh, Dr. Preeti Rastogi

16

To Compare Outcome Of Open Reduction & Internal Fixation In Anterior Mandibular Fracture By Use Of Lag Screws And Miniplates - An In Vivo Study

Dr. Anjani Kumar Jha, Dr. Tauseef Fazal, Dr. Shahid Eqbal, Dr. Vivek Kumar, Dr. Ashiq Hussan Ansari, Dr. Akash Ganguly

23

Comparative Evaluation of the Impact of Bioactive Glass and Its Combination with Proanthocyanidin on Apical Microleakage of Root End Filling Material: A Confocal Laser Scanning Microscope Study

Dr. Harpreet Singh Chhabra, Dr. Ikshita Deshwal, Dr. Sanjeev Kumar Srivastava, Dr. Kshiti Bhardwaj, Dr. Aditya Singh, Dr. Preeti Rastogi

29

CASE REPORTS

Management of A C-Shaped Root Canal System: A Case Report

Dr. Samiksha, Dr. Amit Kumar, Dr. Ankit Kumar Saha, Dr. Rajan jha, Dr. Qainaat shaukat, Dr. Rashmi kashyap

36

Radix Entomolaris - A Unique Clinical barrier to Avoid Endodontic Failure: A Case Report

Dr. Sabya Sachi, Dr. Ajeet kumar, Dr. R. K. Divya, Dr. Amit Kumar, Dr. Rajnish Kumar, Dr. Ankit Kumar Saha

41

The Management of Maxillary Midline Diastema - A Clinical Case Report	
<i>Dr. Nabeel Aftab, Dr. Abhishek Singha Roy, Dr. Santosh Kumar, Dr. Ravi Ranjan, Dr. Kaushal Mishra, Dr. Alok Kumar</i>	46
Utility Arch: Transforming Upper Incisor Alignment Effectively	
<i>Dr. Ravi Ranjan, Dr. Abhishek Singha Roy, Dr. Mehedi Hasan, Dr. Shivangi Kumari, Dr. Nabeel Aftab, Dr. Kumari Anuradha</i>	52
Prosthetic management of missing teeth – A Case Report	
<i>Dr. Taskin Khan, Dr. Eeraveni Ranadheer, Dr. Sunaina Bharti, Dr. Richa Bharti, Dr. Simmi Priya</i>	56
Operculectomy: A Case Report	
<i>Dr. Smriti Priya, Dr. Eeraveni ranadheer, Dr. Anil Kohli, Dr. Shafaque Muskan, Dr. Kumari Rani</i>	59
Frenectomy - A Case Report	
<i>Dr. Rohit Bharadwaj, Dr. Ria Jha, Dr. Kausar Parwez Khan, Dr. Uzwal Kumar Jha, Dr. Akshta</i>	62
Gingival Depigmentation Using Scalpel Technique: A Case Report	
<i>Dr. Mithilesh Bhagat, Dr. Raghav Narayan Jha, Dr. Kausar Parwez Khan, Dr. Amjad Tasheen, Dr. Iswar Chandra Vidyasagar</i>	67
Surgical management of odontogenic keratosis (OKC) - A Case Report	
<i>Dr. Anjani Kumar Jha, Dr. Gautam Kumar, Dr. Tauseef Fazal, Dr. Priyabrat Panda, Dr. Barirah Anwar, Dr. Purushottam Jha</i>	71
Denture Rebasing: A Case Report – Giving Your Denture A Second Chance	
<i>Dr. Abhishek Ghosh, Dr. Suvajit Adak, Dr. Sudheer Arunachalam, Dr. Priya, Dr. Abhilash Srivastava</i>	76

To Evaluate Extraoral (Kurt Thoma) Vs Intraoral (Vazirani Akinosi) Technique Of Mandibular Nerve Block In Mandibular Teeth Extraction

Abstract

Introduction: Effective anesthesia is vital for pain control during mandibular tooth extraction. The inferior alveolar nerve block (IANB) is widely used; however, conventional techniques fail in over 20% of cases due to anatomical variability and technique sensitivity. Modified methods like the extraoral Kurt Thoma (KT) and intraoral Vazirani–Akinosi (VA) techniques offer alternative solutions, especially in patients with restricted mouth opening. This study aimed to compare the clinical efficacy, onset time, pain perception, and complications associated with these two approaches.

Materials and Methods: A randomized, prospective split-mouth study was conducted on 23 patients requiring bilateral mandibular tooth extractions. Each patient received both techniques on contralateral sides—KT on one side and VA on the other. Parameters evaluated included mouth opening (pre- and postoperatively), onset of anesthesia (subjective and objective), pain during injection (Visual Analog Scale), incidence of positive aspiration, need for supplemental injections, and complications such as trismus, hematoma, or paresthesia. Follow-up was conducted for five days postoperatively.

Results: Both techniques significantly improved postoperative mouth opening, with no significant intergroup difference. The VA technique had a slightly faster onset of anesthesia, though the difference was not statistically significant. Pain during injection was mild to moderate in both groups, with similar VAS scores. Positive aspiration occurred in 8.7% of KT and 13.0% of VA cases. Supplemental anesthesia was required in 21.7% of KT and 17.4% of VA cases. Minor complications such as trismus were observed (13.0% KT; 8.7% VA), with no cases of hematoma or paresthesia.

Conclusion: Both the Kurt Thoma and Vazirani–Akinosi techniques are effective and safe alternatives to conventional IANB, particularly in cases with limited mouth opening. With proper anatomical knowledge and clinical skill, these methods can be reliably integrated into practice. Larger multicentric studies are recommended for further validation.

Dr. Anjani Kumar Jha¹
Dr. Prity Kumari²
Dr. Tauseef Fazal³
Dr. Ashish Kumar⁴
Dr. Ashiq Hussan Ansari⁵
Dr. Akash Ganguly⁶

*jha.anjanikumar235@gmail.com*¹
*pritythakur778@gmail.com*²

Department of Oral and Maxillofacial Surgery.^{1,2,3,4,5,6}
*Prof. and H.O.D.*¹
Post Graduate Trainee.^{1,3,4}
Associate Professor^{3,4}
Senior lecturer.^{5,6}

Mithila Minority Dental College and Hospital, Darbhanga, Bihar.^{1,2,3,4,5,6}

Corresponding Author

Dr. Prity Kumari

PGT, Department of Oral and Maxillofacial Surgery, Mithila Minority Dental College and Hospital, Darbhanga

Email: pritythakur778@gmail.com

INTRODUCTION

Mandibular tooth extraction is one of the most commonly performed dental procedures, and effective pain control is essential for patient comfort and procedural success. Local anesthesia, particularly the inferior alveolar nerve block (IANB), is the mainstay for numbing the mandibular teeth, gingiva, lower lip, tongue, and floor of the mouth.¹ However, despite its widespread use, the conventional IANB—relying on intraoral landmarks such as the coronoid notch and pterygomandibular raphe—fails in over 20% of cases due to anatomical variability, inaccurate needle placement, and inadequate needle depth, with common complications including positive aspiration and nerve injury.^{2,3}

To overcome these limitations, modified techniques have been introduced. The Gow-Gates technique boasts a broader anaesthetic distribution and a lower aspiration rate (~2%), though it has a slower onset time compared to conventional IANB.⁴ Approaches like Boonsiriseth's soft-tissue-sparing technique aim to reduce pain and complication risk by minimizing periosteal trauma, while extraoral landmark-based methods—such as the Kurt Thoma and more recent extra-intraoral techniques—incorporate reliable bony landmarks (e.g., the posterolateral mandibular ramus) to guide needle placement more accurately.^{5,6} These innovations strive to enhance block success, reduce onset time, and improve safety. This study aims to compare the efficacy, onset time, and complication rate of the conventional direct IANB against an extra-intraoral landmark-guided technique.

MATERIALS AND METHOD

This randomized prospective split-mouth study was conducted in the Department of Oral and Maxillofacial Surgery, Mithila Minority Dental College and Hospital, Darbhanga, Bihar. A total of 23 patients requiring bilateral mandibular tooth extractions were selected based on the inclusion and exclusion criteria.

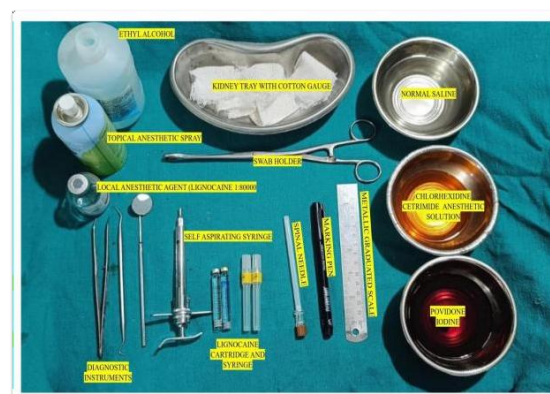

Fig-1: Armamentarium

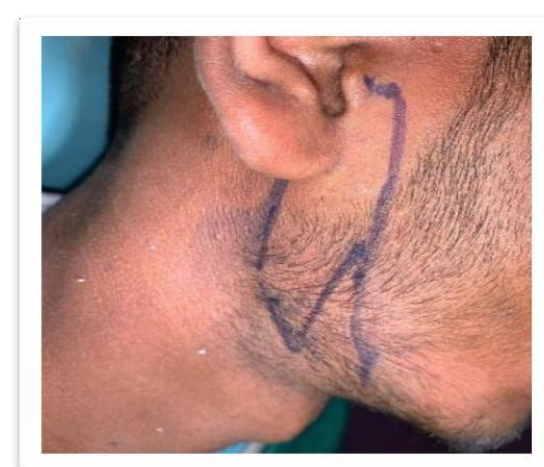


Fig-2: Surface marking for Kurt Thoma Technique.

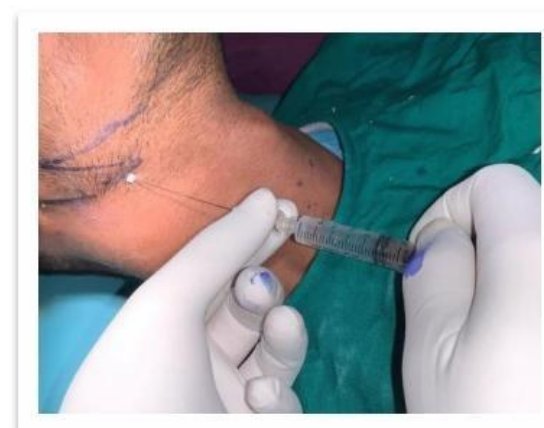

Fig-3: A Deposition of injection by Kurt Thoma technique (Extraoral)

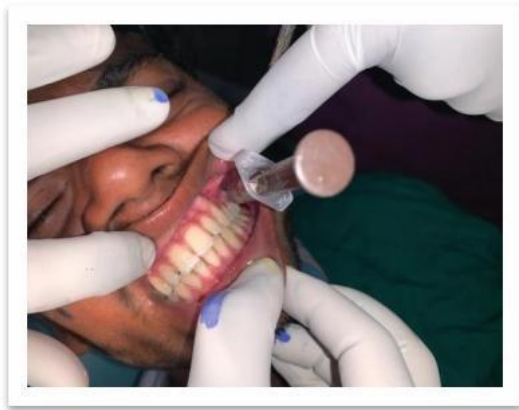

Fig-4: Deposition of injection by Vazirani Akinosi technique (Intraoral)

STUDY GROUPS

The two study groups were defined as follows:

- **Group 1:** Extraoral nerve block using Kurt Thoma technique
- **Group 2:** Intraoral nerve block using Vazirani–Akinosi technique

Each patient received both techniques on contralateral sides using a split-mouth design.

INCLUSION CRITERIA

The two study groups were defined as follows:

- Patients of any age and gender
- Patients requiring extraction of bilateral mandibular teeth
- Patients with restricted mouth opening

EXCLUSION CRITERIA

The two study groups were defined as follows:

- Presence of active infection, swelling, or abscess at the injection site
- Patients with systemic contraindications to local anesthesia or minor oral surgery
- Patients unwilling to provide informed consent

STUDY GROUPS

The All patients underwent a complete preoperative evaluation including:

1. **Bleeding Time:** Blotting paper method
2. **Clotting Time:** Capillary tube method
3. **Complete Blood Count (CBC)**
Glycated Haemoglobin (HbA1c)
4. **Viral Markers:** HBsAg and HIV

ARMAMENTARIUM

Standard armamentarium (Fig.1.) included diagnostic instruments, antiseptic solutions (povidone-iodine, chlorhexidine with cetrimide), local anesthetic (2% lignocaine with 1:80,000 adrenaline), 21-gauge disposable and spinal needles, self-aspirating cartridge syringes, and measuring tools.

ANESTHETIC TECHNIQUES

Group 1 – Kurt Thoma Technique (Extraoral Approach)

he patient was positioned upright. The anterior border of the masseter was palpated with the patient clenching their teeth. A line was drawn from this point to the tragus, and its midpoint was marked. A second line was drawn vertically from this midpoint, parallel to the posterior border of the mandible (Fig.2.) After disinfection and surface infiltration, a 21-gauge spinal needle was inserted along the marked line to the predetermined depth (7–8 cm) until the position corresponding to the mandibular foramen was reached. Local anesthetic was slowly deposited after negative aspiration (Fig. 3.)

Group 2 – Vazirani–Akinosi Technique (Intraoral Approach)

With the patient in occlusion, the needle was inserted at the level of the maxillary mucogingival junction, parallel to the occlusal plane, and advanced 2.5–3 cm between the medial ramus and maxillary tuberosity. A total of 1.5–1.8 mL of anesthetic was deposited after negative aspiration (Fig. 4.)

EVALUATION PARAMETERS

Mouth Opening: Measured pre- and postoperatively using a stainless steel scale from the incisal edges.

1. Onset of Anesthesia:

- **Subjective:** Tingling or numbness reported by the patient in the lip, buccal mucosa, or tongue.
- **Objective:** Assessed using a sharp explorer for tissue probing in nerve-distribution zones.

2. Pain on Injection:

Rated using the Visual Analog Scale (VAS: 0–10).

3. Positive Aspiration:

Recorded as "Yes" or "No".

4. Supplemental Injection

Requirement: Noted if additional anesthesia was needed.

5. Complications:

Hematoma, trismus, or paresthesia were monitored immediately and during a 5-day follow-up. Paresthesia was evaluated by sensory testing with gauze while the patient's eyes were closed.

POSTOPERATIVE PROTOCOL

Standard postoperative instructions were given, including pressure pack placement, dietary advice, and oral hygiene. Medication prescribed included:

- Amoxicillin-clavulanic acid 625 mg TID (5 days)
- Metronidazole 400 mg TID (5 days)
- Paracetamol + Aceclofenac BID (3 days)
- Pantoprazole 40 mg OD (before breakfast)

Patients were recalled on the 5th postoperative day for complication assessment.

RESULT

The study compared two techniques for inferior alveolar nerve block (IANB)—Kurt Thoma (extraoral) and Vazirani–Akinosi (intraoral)—based on several clinical parameters. Below are the comparative outcomes for each group across six evaluated parameters:

Mouth Opening

Mouth opening improved postoperatively in both groups. The difference between pre- and postoperative values was statistically significant within groups, but not between groups ($p > 0.05$) (Table 1.)

Table 1

Technique	Preoperative (mm)	Postoperative (mm)
Kurt Thoma	24.6 ± 4.2	28.1 ± 3.7
Vazirani–Akinosi	25.1 ± 4.5	29.0 ± 4.1

Onset of Anesthesia

The Vazirani–Akinosi technique demonstrated a slightly faster onset of anesthesia, both subjectively and objectively, although the differences were not statistically significant ($p > 0.05$) (Table 2.)

Table 2

Technique	Subjective Onset (min)	Objective Onset (min)
Kurt Thoma	3.8 ± 0.3	4.2 ± 0.4
Vazirani–Akinosi	3.5 ± 0.3	3.9 ± 0.4

Pain on Injection (VAS Score)

VAS scores indicated that most patients experienced mild to moderate pain during injection in both groups, with no significant difference in pain perception (Table 3.)

Table 3

Technique	No Pain	Mild (1–3)	Moderate (4–6)	Severe (7–10)
Kurt Thoma	0	6 (26.1%)	17 (73.9%)	0
Vazirani–Akinosi	0	6 (26.1%)	17 (73.9%)	0

Positive Aspiration

Positive aspiration occurred slightly more often in the Vazirani–Akinosi group; however, the difference was not statistically significant ($p > 0.05$) (Table 4.)

Table 4

Technique	Positive Aspiration (%)
Kurt Thoma	2 (8.7%)
Vazirani–Akinosi	3 (13.0%)

Supplemental Injection Requirement

The need for supplemental injections was comparable between the two groups and not statistically significant (Table 5.)

Table 5

Technique	Required Supplemental Injection (%)
Kurt Thoma	5 (21.7%)
Vazirani–Akinosi	4 (17.4%)

Complications

Trismus was the only observed complication and was slightly more frequent in the Kurt Thoma group. No cases of hematoma or paresthesia were reported. (Table 6.)

Table 6

Technique	Trismus (%)	Hematoma	Paresthesia
Kurt Thoma	3 (13.0%)	0	0
Vazirani–Akinosi	2 (8.7%)	0	0

Discussion

In this comparative study between the extraoral Kurt Thoma technique and the intraoral Vazirani–Akinosi (VA) closed-mouth technique, both approaches were found to be effective in achieving mandibular anesthesia for tooth extractions, particularly in patients with limited mouth opening. Despite similar success rates, some clinical distinctions merit attention.

Onset of anesthesia was marginally faster in the VA group, with most patients experiencing subjective symptoms within 3.5–4 minutes, consistent with previous studies reporting a faster onset for intraoral closed-mouth techniques due to more accurate anesthetic deposition closer to the nerve trunk.^{7–9} Conversely, the slower onset in the Kurt Thoma technique may be attributed to the greater diffusion distance, as precise identification of the mandibular foramen is more difficult via the extraoral route.¹⁰

Pain perception, assessed via Visual Analog Scale (VAS), was not significantly different between the two groups, aligning with findings from Mahajan et al. and Donkor et al.^{11,12} However, patients in the extraoral group showed higher anxiety, likely due to the longer needle and unfamiliarity with the technique. Pain during injection is influenced by factors such as injection speed, tissue distension, and solution pH, rather than the approach alone.¹³

Mouth opening increased significantly after anesthesia in both groups, with no significant intergroup differences, reflecting successful motor blockade of the masticatory muscles by both techniques⁵. This functional gain is crucial in trismus patients where traditional IANB or Gow-Gates techniques are not feasible.^{4,14}

Positive aspiration, a concern for intravascular injection, occurred at similar frequencies (8.7% vs. 13.0%) in both groups, showing no statistical significance. While the classical IANB has a reported aspiration rate of up to 15%³, the VA technique is known to reduce this risk due to the posterior needle path⁸. Our findings echo reports by Jendi and Thomas, who found a low aspiration incidence with the VA approach compared to Halstead's method.¹⁵

Supplementary injections for buccal nerve anesthesia were required in both groups (17.4% vs. 21.7%), consistent with anatomical variations in the innervation of the buccal mucosa.¹⁶ Although slightly higher in the Kurt Thoma group, the difference was statistically insignificant. Prior studies have also highlighted the need for supplemental buccal infiltration with both VA and extraoral blocks.^{9,17}

Complications were minimal. A few patients developed transient trismus (8.7% in VA, 13.0% in KT), which resolved without intervention. No cases of hematoma, nerve damage, or infection were recorded, highlighting the safety of both techniques when proper asepsis and anatomical knowledge are applied.^{18,19}

Despite the favourable results, limitations include a small sample size and the use of bilateral sites in the same patient, which could introduce crossover bias. Additionally, long-term outcomes and patient-reported satisfaction were not assessed. Future multicentric trials with larger cohorts and longer follow-up are warranted to establish generalizable conclusions.²⁰

The VA technique remains a reliable method in cases of trismus or where conventional landmarks are inaccessible, though it may be limited by maxillary posterior tooth loss or anatomical variation²¹. Meanwhile, the Kurt Thoma technique offers a valuable alternative in severe trismus or fibrotic conditions where intraoral access is restricted.²²⁻²⁴

Both the intraoral VA and extraoral KT techniques provide comparable anesthesia success and safety for mandibular extractions, especially in cases with limited mouth opening. Operator expertise, anatomical familiarity, and patient selection remain critical to technique choice.

CONCLUSION

The present study demonstrates that both the Kurt Thoma and Vazirani-Akinosi techniques are effective alternatives to the conventional inferior alveolar nerve block (IANB), offering comparable success rates and onset of anesthesia. These techniques provide advantages such as consistent anatomical landmarks, reduced risk of positive aspiration, and suitability in cases with limited mouth opening. With appropriate anatomical knowledge and clinical training, they can be reliably incorporated into routine practice. Future studies with larger sample sizes are recommended to validate and strengthen these findings.

REFERENCES

1. Malamed SF. Handbook of Local Anesthesia. 5th ed. St. Louis: Mosby; 2004.
2. Madan GA, Madan SG, Madan G, Madan AD. Failure of inferior alveolar nerve block: exploring the alternatives. J Am Dent Assoc. 2002;133(7):843-6.

3. Dover WS. Anaesthesia of the mandibular teeth. *J Dent Assoc S Afr.* 1971;26(8):373–7.
4. Gow-Gates GAE. Mandibular conduction anesthesia: a new technique using extraoral landmarks. *Oral Surg Oral Med Oral Pathol.* 1973;36(3):321–30.
5. Boonsiriseth K, Sirintawat N, Arunakul S, Wongsirichat N. Comparative study of the novel modified intraoral technique and two classic techniques for inferior alveolar nerve block. *Int J Oral Maxillofac Surg.* 2013;42(7):852–6.
6. Waikakul A, Punwutikom J. A comparative study of the two techniques of inferior alveolar nerve block. *J Oral Maxillofac Surg.* 1989;47(2):90–5.
7. Roy B, Talukdar D. Comparative evaluation of efficacy of Vazirani-Akinosi technique with conventional inferior alveolar nerve block in patients with trismus. *J Dent Anesth Pain Med.* 2019;19(3):167–72.
8. Goldberg S, Reader A, Drum M, Nusstein J, Beck M. Comparison of the anesthetic efficacy of the Gow-Gates and Vazirani-Akinosi techniques. *J Endod.* 2008;34(11):1308–11.
9. Vadlamudi A, Sanivarapu S, Vemula S, Koppolu P, Mallineni S, Nuvvula S. Comparative evaluation of the efficacy of three different techniques of inferior alveolar nerve block in children: An in vivo study. *J Dent Anesth Pain Med.* 2020;20(2):111–6.
10. Karthikeyan A, Gnanaseelan R, Shanmugasundaram N. A clinical comparison of extraoral and intraoral techniques for inferior alveolar nerve block in cases with restricted mouth opening. *J Dent Anesth Pain Med.* 2024;24(2):120–5.
11. Mahajan H, Bansal A, Handa S, Wadhwa J, Gupta N. Comparison of conventional inferior alveolar nerve block and Vazirani-Akinosi closed-mouth mandibular nerve block: A randomized clinical trial. *J Dent Anesth Pain Med.* 2022;22(1):45–50.
12. Donkor P, Wong J, Luboga S. An evaluation of the Vazirani-Akinosi technique of mandibular nerve anaesthesia. *Int J Oral Maxillofac Surg.* 1990;19(4):216–9.
13. Smith J, Evans T, Mayhew A, Griffin CJ. Factors influencing the pain of local anaesthesia: a review. *J Pain Res.* 2018;11:115–20.
14. Akinosi JO. A new approach to the mandibular nerve block. *Br J Oral Surg.* 1977;15(2):83–7.
15. Jendi S, Thomas R. Comparison of incidence of positive aspiration and efficacy between the Vazirani-Akinosi technique and Halstead technique in dental anesthesia: A randomized clinical trial. *J Dent Anesth Pain Med.* 2020;20(1):35–40.
16. Coleman RD, Smith RA. Distribution of the buccal nerve in the mandible. *Oral Surg Oral Med Oral Pathol.* 1982;54(2):148–53.
17. Yucel E, Hutchison IL. Buccal nerve anaesthesia: a comparative study of two techniques. *Aust Dent J.* 1995;40(1):15–6.
18. Hwang CK, Kwon SR, Huh KH, Kim JS, Kim MS, Lee SR. Complications related to inferior alveolar nerve block anesthesia: a retrospective study. *J Dent Anesth Pain Med.* 2018;18(4):237–43.
19. Menon VD, Garg K, Dhasmana S, Kalra N, Verma S. Evaluation of the efficacy of various local anesthesia techniques in patients with irreversible pulpitis: a randomized controlled trial. *J Dent Anesth Pain Med.* 2020;20(4):211–6.
20. Johnson TM, Badovinac RL, Shaefer JR. Teaching alternative inferior alveolar nerve block techniques: clinical implications. *J Dent Educ.* 2007;71(9):1145–52.
21. Palti DG, Almeida FC, Andreo JC, Dionísio TJ, Bezerra RF. Anatomical variations in the mandibular foramen: implications for Vazirani-Akinosi and Gow-Gates techniques. *J Appl Oral Sci.* 2011;19(1):11–5.
22. Raza A, Shafique S, Rahman AU, Ahsan SH, Khan A. Extraoral approach for inferior alveolar nerve block in patients with restricted mouth opening. *J Pharm Res Int.* 2021;33(46):21–30.

23. Sowmya MV, Natarajan S, Rajesh B, Sangeetha P. Extraoral inferior alveolar nerve block: An underutilized technique in modern dental practice. *J Dent Anesth Pain Med*. 2021;21(2):113–8.
24. Suazo Galdames IC, Zavando MA, Smith RL. Anatomical study of the mandibular foramen location related to the use of anesthetic techniques. *Oral Med Oral Patol Oral Cir Bucal*. 2008;13(4):E247–50.
25. Mishra S, Singh R, Kumar S. Clinical efficacy of Vazirani-Akinosi technique for mandibular anesthesia in patients with trismus: a clinical study. *J Clin Anesth*. 2012;24(5):402–6

To Evaluate The Efficacy of 4% Articaine Versus 2 % Lignocaine In Mandibular Third Molar Surgery

Abstract

Introduction: Effective local anaesthesia is vital in oral surgery, especially for procedures like mandibular third molar extractions. While 2% lignocaine remains widely used, 4% articaine has gained attention due to its enhanced pharmacokinetics. This study aimed to compare the efficacy of 4% articaine with 1:100,000 epinephrine and 2% lignocaine with 1:100,000 epinephrine in terms of time of onset, duration, pain perception, and hemodynamic stability.

Materials and Methods: A randomized split-mouth clinical trial was conducted on 18 patients (36 sites) requiring bilateral mandibular third molar removal. Group 1 received 2% lignocaine, and Group 2 received 4% articaine. Standardized inferior alveolar, lingual, and long buccal nerve blocks were administered. Pain scores (VAS), onset time, anaesthetic duration (subjective and objective), and hemodynamic parameters (blood pressure, pulse rate, oxygen saturation) were recorded.

Results: Pain during injection was significantly lower in the articaine group, with 50% reporting no pain ($p < 0.001$). Onset of anaesthesia was faster with articaine (83.3% at 3 min vs. 61.1% at 4 min for lignocaine). Articaine also provided longer anaesthetic duration, maintaining effect up to 120 minutes in 50% of patients. No significant differences in hemodynamic responses were observed.

Conclusion: Articaine 4% with epinephrine demonstrated faster onset, longer duration, and better pain control than lignocaine, with similar safety. It is a viable alternative for oral surgical procedures.

Keywords: Articaine; lignocaine; anaesthesia

Dr. Anjani Kumar Jha¹
Dr. Anil Kumar²
Dr. Tauseef Fazal³
Dr. Ashish Kumar⁴
Dr. Ashiq Hussan Ansari⁴
Dr. Akash Ganguly⁴
Dr. Madhukar Kumar⁴

*jha.anjanikumar235@gmail.com*¹
*nil.pandit25@gmail.com*²

Department of Oral and Maxillofacial Surgery.^{1,2,3,4}
*Prof. and H.O.D.*¹
*Post Graduate Trainee.*²
*Reader.*³
*Senior lecturer.*⁴

Mithila Minority Dental College and Hospital, Darbhanga, Bihar.^{1,2,3,4}

Corresponding Author

Dr. Anil Kumar

PGT, Department of Oral and Maxillofacial Surgery, Mithila Minority Dental College and Hospital, Darbhanga

Email: *nil.pandit25@gmail.com*

INTRODUCTION

Effective pain control is fundamental in oral and maxillofacial surgery, with local anaesthesia playing a pivotal role in ensuring patient comfort and procedural success. Among various dental procedures, mandibular third molar surgery remains one of the most common and often challenging, requiring profound and prolonged anaesthesia for patient cooperation and optimal outcomes. The two most widely used local anaesthetic agents in dental practice are lignocaine (lidocaine) and articaine, each with distinct pharmacological properties influencing their onset, potency, and duration of action. Lignocaine has long been considered the gold standard due to its well-established safety profile and predictable effects, while articaine, a relatively newer amide anaesthetic with an additional ester group, offers unique advantages such as enhanced lipid solubility, better bone penetration, and a faster onset of action¹⁻³.

Several studies have attempted to compare the efficacy of articaine and lignocaine, especially in the context of inferior alveolar nerve blocks and buccal infiltrations during third molar surgeries. Articaine's thiophene ring and high protein binding contribute to its superior diffusion and extended anaesthetic effect, making it particularly effective in dense mandibular bone²⁻⁴. Moreover, its rapid plasma metabolism results in a shorter half-life, reducing systemic toxicity and allowing for safer reinjections if required [5]. Previous clinical trials have demonstrated that articaine may provide deeper anaesthesia and longer duration compared to lignocaine, with similar or reduced incidence of adverse reactions [1,3,6]. Considering these findings, the present study aims to evaluate and compare the clinical efficacy of 4% articaine with 1:100,000 epinephrine versus 2% lignocaine with 1:100,000 epinephrine in patients undergoing mandibular third molar surgery.

MATERIALS AND METHOD

This randomized clinical trial was undertaken to evaluate and compare the clinical efficacy of 2% lignocaine hydrochloride with 1:100,000 epinephrine and 4% articaine hydrochloride with 1:100,000 epinephrine in the surgical removal of bilateral mandibular third molars (Fig.1.) The study was conducted at the Department of Oral and Maxillofacial Surgery, Mithila Minority Dental College and Hospital, and was approved by the institutional ethical committee. A total of 18 patients requiring bilateral mandibular third molar

extraction participated in the study, comprising 36 surgical sites. All patients provided informed written consent.

The digital photographs of the subjects were taken using digital SLR camera, the head of the subjects were positioned so that the Frankfort horizontal plane and the inter pupillary line were parallel to the surface of the floor. photographs were cropped using Adobe photoshop Cs. Cropped photographs were transferred to computer loaded with Digimizer software for the evaluation of facial asymmetry. The photographs from groups were analysed for five horizontal and three midline parameters using Digimizer software after identification of required landmarks.

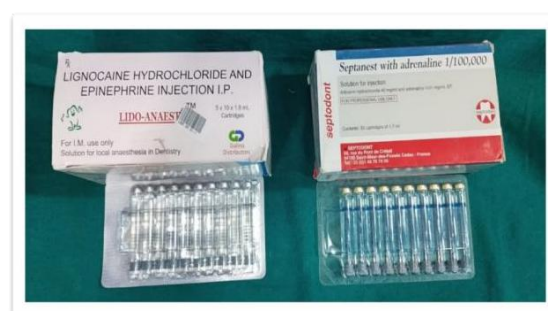

Fig-1: Lignocaine (left) and Articaine (Right)

Inclusion Criteria

- Patients aged between 18 and 55 years.
- ASA I and ASA II physical status.
- Patients requiring bilateral mandibular third molar extraction.
- Teeth deemed non-restorable and indicated for surgical removal.
- Willingness to participate and comply with the study protocol.

Exclusion Criteria

- ASA physical status III or above.
- History of allergy to local anaesthetics or sulfites.
- Pregnant or lactating women.
- Presence of infection or soft tissue lesion at the injection site.

- History of chronic alcohol or drug abuse.
- Inability to comprehend Visual Analog Scale (VAS).
- Unwillingness or inability to provide informed consent.

Randomization and Study Design

A split-mouth randomized design was used. The side to be anesthetized with lignocaine or articaine was determined by the closed-chit method. Each patient received one anaesthetic agent on one side, followed by the other agent on the contralateral side during a subsequent visit.

Anesthetic Procedure

Standard nerve blocks (inferior alveolar, lingual, and long buccal) were administered in both groups. Group I received 2% lignocaine with 1:100,000 epinephrine, while Group II received 4% articaine with 1:100,000 epinephrine. Anaesthetic techniques followed the classical Halstead approach as described by Malamed. Onset and duration of anaesthesia were assessed using both subjective (patient-reported symptoms) and objective (pin-prick and probing response) methods.

Outcome Parameters

Four parameters were recorded and evaluated:

1. **Pain during injection and surgery** — assessed using the Visual Analog Scale (VAS).
2. **Onset of anaesthesia** — recorded at 2, 2.5, 3, 3.5, and 4 minutes intervals post-injection.
3. **Hemodynamic parameters** — including systolic and diastolic blood pressure, pulse rate, and oxygen saturation at baseline, 15

minutes after injection, and 30 minutes post-extraction.

4. **Duration of action** — determined by both subjective sensation return and objective pain response upon probing at regular time intervals (45, 60, 90, 120, and 180 minutes).

All surgical procedures were performed with sterilized armamentarium (Fig.2. – Fig.5.), postoperative care, and data recordings were performed under standardized conditions. Antibiotic and analgesic prophylaxis included amoxicillin-clavulanic acid and a combination of ibuprofen and paracetamol, administered thrice daily for three days.

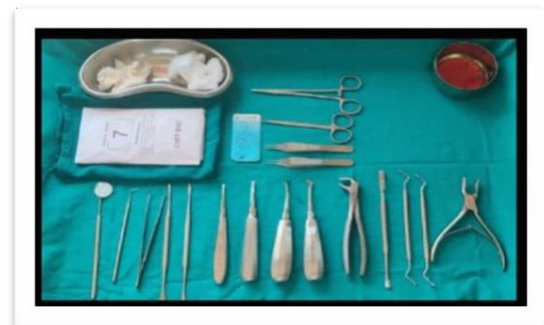

Fig-2: Extraction Instruments

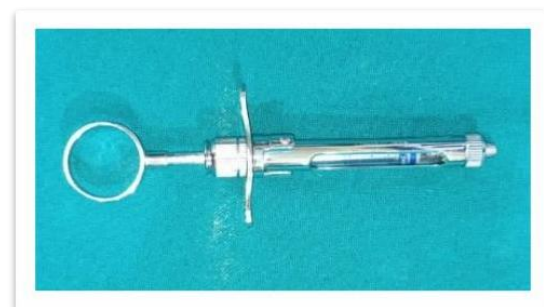

Fig-3: Aspirating Dental Injection

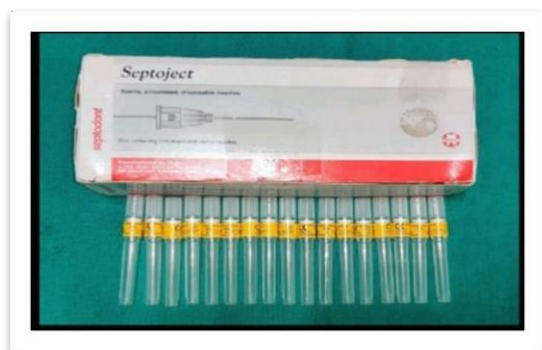

Fig-4: Gauge Needle (35mm)

RESULT

A total of 18 patients (36 sites) undergoing bilateral mandibular third molar surgery were evaluated for the comparative anaesthetic efficacy of 2% lignocaine (Group 1) and 4% articaine (Group 2), both with 1:100,000 epinephrine. Pain perception during injection and surgery was significantly lower in the articaine group. While 50% of subjects in Group 2 reported no pain and 50% reported mild pain, in Group 1, 72.2% experienced moderate pain and 27.8% reported mild pain (Table 1; $p < 0.001$).

The onset of anaesthesia, evaluated using objective symptoms, was faster in Group 2. By 3 minutes, 83.3% of subjects receiving articaine showed signs of effective anaesthesia in the inferior alveolar, lingual, and long buccal nerve blocks. In contrast, lignocaine's onset was delayed, with only 38.9% of subjects exhibiting anaesthesia at 3.5 minutes and 61.1% at 4 minutes (Table 2). This confirms the faster onset profile of articaine across all tested nerve blocks.

Regarding the duration of action, both objective (pain on probing) and subjective (patient-reported sensation return) symptoms persisted longer in the articaine group. Pain on probing appeared earlier in the lignocaine group (44.4% at 60 min and 55.6% at 90 min) whereas in the articaine group, 50% of patients retained anaesthesia until 120 minutes (Table 3). Similarly, subjective loss of numbness began at 60 minutes in Group 1, while in Group 2, it extended beyond 120 minutes in 50% of cases (Table 4). These findings suggest that articaine offers prolonged anaesthetic duration compared to lignocaine, which may enhance clinical efficiency in extended surgical procedures.

Table 1: Pain During Injection and Surgery (VAS Score)

VAS Score	Group 1 (Lignocaine)	Group 2 (Articaine)	p-value
No pain	0 (0.0%)	9 (50.0%)	<0.001 *
Mild pain	5 (27.8%)	9 (50.0%)	
Moderate pain	13 (72.2%)	0 (0.0%)	
Severe pain	0 (0.0%)	0 (0.0%)	

Table 2: Onset of Anesthesia (Objective Symptoms)

Time	IANB (%)	LNB (%)	LBNB (%)	Group
2.5 min	0	0	0	Lignocaine
3.0 min	0	0	0	Lignocaine
3.5 min	38.9	38.9	38.9	Lignocaine
4.0 min	61.1	61.1	61.1	Lignocaine
2.5 min	16.7	16.7	16.7	Articaine
3.0 min	83.3	83.3	83.3	Articaine

Table 3: Duration of Action (Objective Symptoms - Pain on Probing)

Time (min)	IANB (%)	LN B (%)	LBN B (%)	Group
60	44.4	44.4	44.4	Lignocaine
90	55.6	55.6	55.6	Lignocaine
90	50.0	50.0	50.0	Articaine
120	50.0	50.0	50.0	Articaine

Table 4: Duration of Action (Subjective Symptoms)

Time (min)	IAN B (%)	LN B (%)	LBN B (%)	Group
60	44.4	44.4	44.4	Lignocaine
90	55.6	55.6	55.6	Lignocaine
90	50.0	50.0	50.0	Articaine
120	50.0	50.0	50.0	Articaine

DISCUSSION

The present study compared the clinical efficacy of 4% articaine with 1:100,000 epinephrine to that of 2% lignocaine with 1:100,000 epinephrine in the context of mandibular third molar surgery. Our results indicate that articaine provides a faster onset of anaesthesia, longer duration of action, and better pain control during injection and surgery compared to lignocaine. These findings are consistent with several previously published studies that underscore the enhanced pharmacological profile of articaine [1–3].

The faster onset of anaesthesia observed with articaine may be attributed to its lower pKa (7.8), enabling more rapid diffusion through nerve membranes, as well as its thiophene ring structure that enhances lipid solubility and tissue penetration [4,5]. Maruthingal et al. and Isen have both highlighted these advantages in clinical and pharmacological contexts [4,5]. Moreover, articaine's partial ester structure allows for dual metabolism in both plasma and liver, reducing systemic toxicity and allowing safer reinjection if necessary [5,6]. These features have made articaine particularly valuable for procedures requiring extensive anaesthesia and prolonged surgical times.

Pain perception, a critical factor in patient compliance and comfort, was significantly lower with articaine in our study. This agrees with findings from Jain et al., Raj et al., and other randomized controlled trials, where patients reported lower discomfort during administration and fewer requirements for anaesthesia [1,3,7]. Additionally, studies by Ghosh et al. and Somuri et al. demonstrated reduced injection pain and more effective buccal infiltration with articaine, even eliminating the need for palatal injections in some cases [8,9]. Kanaa et al. further supported the

enhanced effectiveness of articaine in mandibular infiltrations [10].

Regarding the duration of anaesthesia, articaine consistently outperformed lignocaine in our study. This outcome supports observations made by Moore et al. and Rebolledo et al., who found articaine to yield significantly longer anaesthetic durations, particularly beneficial in surgical extractions and procedures involving extensive manipulation [11,12]. The high protein-binding capacity of articaine (94%) is likely responsible for this prolonged effect, as previously explained by Costa et al. and Colombini et al. [13,14].

From a safety standpoint, no significant differences were observed in hemodynamic parameters (systolic blood pressure, heart rate, SpO₂) between the two groups in our study, which aligns with the findings of Sharma et al. and Martin et al., who concluded that articaine is equally safe as lignocaine for routine dental use [15,16]. These data reinforce the notion that articaine, when used in recommended concentrations with vasoconstrictors, does not introduce increased cardiovascular risk in healthy individuals.

Articaine's superior performance in nerve block efficacy has also been highlighted in studies comparing it to lidocaine for inferior alveolar nerve blocks, buccal infiltrations, and surgical extraction of impacted third molars [2,17–19]. Bhagat et al. and Kalia et al. confirmed articaine's quicker onset and longer duration in exodontia, while Gregorio et al. emphasized its strong performance in bony procedures [20–22]. Shruthi et al. and Silva et al. found articaine as effective, or superior, to lidocaine with respect to patient-reported outcomes and clinical efficacy [23,24].

Given the growing body of evidence, including our own results, it is evident that articaine holds significant clinical advantages over lignocaine in oral surgical settings, particularly for complex procedures such as third molar surgery. Future investigations involving larger, multicenter trials are warranted to further validate these findings across diverse populations and assess the safety in medically compromised individuals.

CONCLUSION

This randomized clinical trial demonstrated that 4% articaine with 1:100,000 epinephrine provides superior anaesthetic efficacy compared to 2% lignocaine in mandibular third molar surgery. Articaine showed a significantly faster onset of

action, longer duration, and better pain control with no increase in adverse hemodynamic effects. These advantages make articaine a potent, safe, and clinically effective alternative to lignocaine for routine oral surgical procedures. While the findings are promising, broader application of these results requires further validation through multicenter studies with larger sample sizes, diverse populations, and longer follow-up periods to evaluate long-term safety, effectiveness, and patient satisfaction in varied clinical settings.

REFERENCES

1. Jain NK, John RR. Anesthetic efficacy of 4% articaine versus 2% lignocaine during the surgical removal of the third molar: A comparative prospective study. *Anesth Essays Res.* 2016;10(2):356–61.
2. Kambalimath DH, Dolas RS, Kambalimath HV, Agrawal SM. Efficacy of 4% Articaine and 2% Lidocaine: A clinical study. *J Maxillofac Oral Surg.* 2013;12(1):3–10.
3. Raj Y. Comparison of the Effectiveness of 4% Articaine Hydrochloride and 2% Lignocaine Hydrochloride in Impacted Mandibular Third Molar Surgery: A Prospective, Parallel Arm, Randomized Controlled Trial. *Saudi J Biomed Res.* 2021;6(6):168–73.
4. Maruthingal S, Mohan D, Maroli RK, Alahmari A, Alqahtani A, Alsadoon M. A comparative evaluation of 4% articaine and 2% lidocaine in mandibular buccal infiltration anesthesia: A clinical study. *J Int Soc Prev Community Dent.* 2015;5(6):463.
5. Isen DA. Articaine: pharmacology and clinical use for local and regional anesthesia. *Dent Today.* 2000;19(11):72–7.
6. Malamed SF, Gagnon S, Leblanc D. Articaine hydrochloride: A study of the safety of a new amide local anesthetic. *J Am Dent Assoc.* 2001;132(2):177–85.
7. Kumar K, Singh R, Kumar S, Gupta J, Kumar A, Verma A. Efficacy of 2% Lignocaine and 4% Articaine in Oral Surgical Procedure: A Comparative Study. *J Contemp Dent Pract.* 2020;21(10):1147.
8. Ghosh A, Basu S, Maity C, Dutta S, Bandyopadhyay S, Dey S. Efficacy of 4% articaine with 1:100,000 adrenaline as an effective alternative for achieving anesthesia during dental extraction. *Indian J Dent Sci.* 2019;11(4):189–95.
9. Somuri AV, Rai AB, Pillai M. Extraction of permanent maxillary teeth by only buccal infiltration of articaine. *J Maxillofac Oral Surg.* 2013;12(2):130–2.
10. Kanaa MD, Whitworth JM, Corbett IP, Meechan JG. Articaine buccal infiltration enhances the effectiveness of lidocaine inferior alveolar nerve block: A prospective randomized double-blind crossover study. *J Endod.* 2006;32(4):296–8.
11. Moore PA, Boynes SG, Hersh EV, DeRossi SS, Sollecito TP, Goodson JM, et al. The anesthetic efficacy of 4% articaine with epinephrine 1:200,000. *J Am Dent Assoc.* 2006;137(11):1572–81.
12. Rebolledo AS, Molina ED, Aytés LB, Escoda CG. Comparative study of the anesthetic efficacy of 4% articaine versus 2% lidocaine in inferior alveolar nerve block during surgical extraction of impacted lower third molars. *Med Oral Patol Oral Cir Bucal.* 2007;12:E139–44.
13. Costa CG, Tortamano IP, Rocha RG, Francischone CE. Onset and duration periods of articaine and lidocaine on maxillary infiltration. *Quintessence Int.* 2005;36(3):197–201.
14. Colombini BL, Modena KC, Calvo AM, Sakai VT, Giglio FP, Dionisio TJ, et al. Articaine and mepivacaine efficacy in postoperative analgesia for lower third molar removal: A double-blind, randomized, crossover study. *Oral Surg Oral Med Oral Pathol Oral Radiol Endod.* 2006;102(2):169–74.
15. Sharma S, Gaur A, Gupta N, Garg A. Comparison of efficacy of 4% articaine and 2% lignocaine in dental extractions. *Int J Oral Health Med Res.* 2014;1(2):17–20.
16. Martin E, Nimmo A, Lee A, Jennings E. Articaine in dentistry: an overview of the evidence and meta-analysis of the latest randomised controlled trials on articaine safety and efficacy compared to lidocaine for routine dental treatment. *Br Dent J.* 2021;230(9):633–40.
17. Kanaa MD, Whitworth JM, Corbett IP,

Meechan JG. Articaine buccal infiltration enhances the effectiveness of lidocaine inferior alveolar nerve block. *Int Endod J*. 2009;42(3):238–46.

18. Haase A, Nusstein J, Beck M, Drum M. Comparing anesthetic efficacy of articaine versus lidocaine as a supplemental buccal infiltration of the mandibular first molar after an inferior alveolar nerve block. *J Am Dent Assoc*. 2008;139(9):1228–35.

19. Saralaya S, Adirajaiah SB, Anehosur V. 4% Articaine and 2% Lignocaine for surgical removal of third molar by mandibular nerve block: A randomized clinical trial for efficacy and safety. *J Maxillofac Oral Surg*. 2019;18(3):405–11.

20. Bhagat MJ, Narayan V, Muthusekhar MR, Jain AR. Comparative study of the anesthetic efficacy of 4% articaine versus 2% lignocaine in the inferior alveolar nerve block during the surgical extraction of impacted mandibular third molars. *Univ Res J Dent*. 2014;4(2):108–14.

21. Kalia V, Supreet, Kaur R. Comparative evaluation of onset and duration of anesthesia of 4% articaine versus 2% lidocaine with epinephrine 1:100,000 during exodontia. *Indian J Compr Dent Care*. 2011;1:19–24.

22. Gregorio LV, Giglio FP, Sakai VT, Modena KC. A comparison of the clinical anesthetic efficacy of 4% articaine and 0.5% bupivacaine (both with 1:200,000 epinephrine) for lower third molar removal. *Oral Surg Oral Med Oral Pathol Oral Radiol Endod*. 2008;106(1):19–28.

23. Shruthi R, Kedarnath N, Mamatha N, Rajaram P, Bhadrashetty D. Articaine for surgical removal of impacted third molar: A comparison with lignocaine. *J Int Oral Health*. 2013;5(6):48–53.

24. Silva LFC, Santos TS, Santos S, Maia MC, Mendonca CG. Articaine versus lidocaine for third molar surgery: A randomized clinical study. *Med Oral Patol Oral Cir Bucal*. 2012;17(1):e140–5.

25. Vahatalo K, Antila H, Lehtinen R. Articaine and lidocaine for maxillary infiltration anesthesia. *Anesth Prog*. 1993;40(4):114–6.

A Comparative Study on Cryogenically and Heat Treated Sodium Hypochlorite on The Fracture Resistance of Endodontically Treated Teeth: An In Vitro Study

Abstract

Objective: To evaluate the effect of cryo-treated and heated sodium hypochlorite (NaOCl) on the fracture resistance of endodontically treated teeth.

Methods: An in vitro study was conducted using 72 freshly extracted human mandibular premolars with single canal. All teeth were decoronated using a carborundum disc to standardize root length to 14 mm. The specimens were randomly assigned to three groups (n = 24 each) based on the temperature of NaOCl used during chemomechanical preparation:

- **Group A:** 5.25% NaOCl at room temperature (25°C)
- **Group B:** 5.25% NaOCl at 2.5°C (cryo-treated)
- **Group C:** 5.25% NaOCl at 60°C (heated)

Following group allocation, canals were prepared using ProTaper rotary files up to size F3. Samples were stored in 100% humidity at 37°C for one week. Fracture resistance was then tested using a universal testing machine, with vertical compressive force applied along the long axis at a crosshead speed of 1 mm/min until fracture. The force at fracture was recorded in Newtons (N).

Conclusion: Group A (room temperature NaOCl) showed the highest mean fracture resistance, followed by Group B (cryo-treated NaOCl), and Group C (heated NaOCl) showed the lowest. The results indicate that elevated irrigation temperature negatively impacts the fracture resistance of endodontically treated teeth. Cryo-treated NaOCl maintains better structural integrity than heated NaOCl but is less effective than room temperature NaOCl.

Keywords: Fracture resistance, Sodium hypochlorite, Cryo-treated NaOCl, Heated NaOCl, Chemomechanical preparation, Endodontically treated teeth.

Dr. Harpreet Singh Chhabra¹

Dr. Ikshita Deshwa²

Dr. Sanjeev Kumar Srivastava³

Dr. Kshiti Bhardwaj⁴

Dr. Aditya Singh⁵

Dr. Preeti Rastogi⁶

harryagar@gmail.com¹

ikshi756@gmail.com²

sanjeevsrivastava409@gmail.com³

drkshitchhabra@gmail.com⁴

aditya.revisited1989@gmail.com⁵

anuradharstg@gmail.com⁶

Department of Conservative Dentistry and Endodontics.^{1,2,3,4,5,6}

Prof. and H.O.D.^{1,3,4}

Post Graduate Trainee.²

Senior lecturer.^{5,6}

Sardar Patel Post Graduate Institute of Dental and Medical Sciences, Lucknow, Uttar Pradesh, India.^{1,2,3,4,5,6}

Corresponding Author

Dr. Harpreet Singh Chhabra

Sardar Patel Post Graduate Institute of Dental and Medical Sciences, Lucknow, Uttar Pradesh, India

Email: *harryagar@gmail.com*

INTRODUCTION

The ultimate goal of endodontic therapy is to achieve effective debridement and disinfection of the root canal system while preserving the structural integrity of the tooth¹. Effective disinfection of the root canal system is fundamental to the long-term success of endodontic treatment². The intricate internal anatomy of the root canal—characterized by narrow canals, fins, isthmuses, and lateral branches—poses a significant challenge to mechanical instrumentation alone³. Therefore, irrigation serves as a critical adjunct by chemically cleansing areas that instruments cannot reach, facilitating the removal of pulp tissue remnants, microorganisms, and the smear layer generated during canal preparation⁴.

Among various irrigants employed, sodium hypochlorite (NaOCl) remains the gold standard owing to its potent antimicrobial activity, ability to dissolve necrotic tissues, and affordability⁵. Despite these advantages, ongoing research has aimed to enhance its efficacy through various modifications, including alteration of concentration, use of surfactants, irrigant agitation techniques (such as sonic, ultrasonic, and negative pressure systems), and temperature modulation⁶.

Among these, temperature alteration of NaOCl has gained considerable attention. Heating NaOCl has been reported to improve its physicochemical properties by increasing chlorine availability and enhancing the rate of organic tissue dissolution⁷. On the other hand, cooling NaOCl, a technique referred to as cryotherapy, is being explored for its potential influence on post-treatment responses and irrigant behavior within the canal system⁸. These modifications may alter the irrigant's penetration, reactivity, and interaction with dentinal structures⁹.

Although these temperature-based strategies have been investigated largely from a chemical and microbiological standpoint, there is a growing need to understand how such alterations may affect the biomechanical behavior of radicular dentin. Since endodontically treated teeth are more susceptible to failure, it becomes imperative to evaluate whether changes in irrigant temperature during chemo-mechanical preparation influence their fracture resistance¹⁰.

In this context, the present in vitro study was undertaken to compare the impact of heated and cryotreated sodium hypochlorite on the fracture resistance of endodontically treated teeth, thereby

contributing to the development of irrigation protocols that support both disinfection and structural preservation.

MATERIALS AND METHOD

Experimental Design:

This in vitro study involved 72 extracted human mandibular premolars with single canals. The specimens were randomly divided into three groups (n = 24 per group) based on the temperature of sodium hypochlorite (NaOCl) used for irrigation during chemo-mechanical preparation:

- Group A: Sodium hypochlorite (5.25%) at room temperature (25°C)
- Group B: Sodium hypochlorite (5.25%) cryo-treated at 2.5°C
- Group C: Sodium hypochlorite (5.25%) heated to 60°C

All specimens underwent standardized chemo-mechanical preparation using the ProTaper Gold rotary file system up to size F3 (30/.09) using the crown-down technique.

Inclusion Criteria

- Extracted single-rooted mandibular premolars
- Teeth with fully formed apices
- Teeth free of developmental anomalies or structural defects

Exclusion Criteria

- Multi-rooted teeth
- Grossly decayed, fractured, or previously restored teeth
- Teeth with internal/external resorption or open apices

Sample Preparation

All extracted teeth were cleaned under running tap water. Stains and calculus were removed using ultrasonic scalers, followed by polishing with pumice powder. The samples were stored in 0.1% thymol in saline to prevent microbial growth, then

autoclaved at 121°C for 15 minutes, and stored in distilled water to prevent dehydration.

Radiographs were taken to confirm the presence of a single canal and to rule out any specimens not meeting the inclusion criteria.

Crowns were sectioned using a carborundum disc under water cooling to achieve a standardized root length of 14 mm(fig.1). Each tooth was wrapped in 0.15 mm-thick aluminum foil, exposing 4 mm of the coronal root surface (fig2). The teeth were then embedded in self-curing acrylic resin using molds (25.4 mm length × 12.7 mm diameter × 1.5 mm thickness) up to the level of the foil(fig 3). After resin setting, the tooth was removed, aluminum scrapped off (fig 4), and light-body silicone impression material was injected into the socket left by the foil to simulate the periodontal ligament. Teeth were repositioned, and excess silicone was trimmed using a No.12 surgical blade (fig 5).

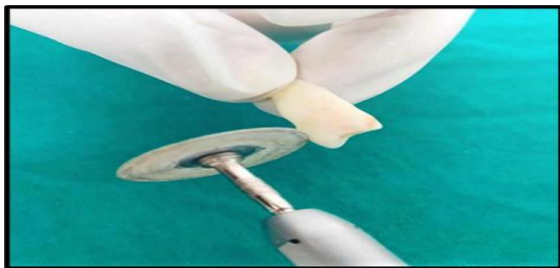


Fig-1: Sectioning to standardize the root length to 14mm.

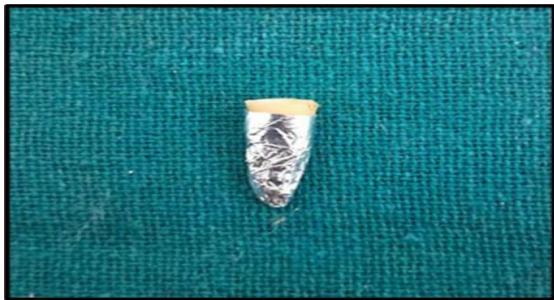

Fig-2: Tooth covered in aluminum foil leaving coronal 4mm.



Fig-3: Tooth placed in the mould.

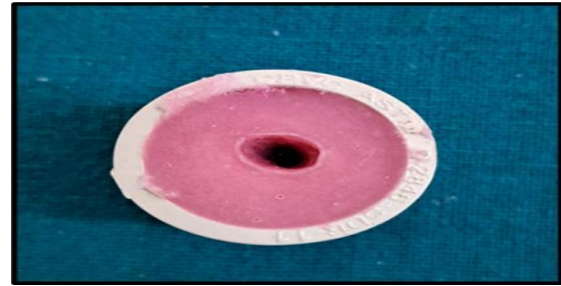


Fig-4: Tooth removed from the mould and foil scrapped off.



Fig-5: After application of light body samples were repositioned.

All specimens were randomly allocated into the following three groups based on irrigation protocol:

- Group A (n = 24): Irrigation with 5.25% NaOCl at room temperature (25°C)
- Group B (n = 24): Irrigation with 5.25% NaOCl cryo-treated to 2.5°C using an ice bath
- Group C (n = 24): Irrigation with 5.25% NaOCl heated to 60°C using a water bath

Canal preparation was carried out using ProTaper Gold files up to F3, with 10 ml of NaOCl at the designated group temperature used per specimen (fig 6).



Fig-6: Chemo-mechanical preparation was done.

After preparation, all samples were stored in 100% humidity at 37°C for 24 hours prior to testing.

Each specimen was positioned vertically in a Universal Testing Machine (UTM). A metal indenter applied a compressive load along the long axis of the tooth at a crosshead speed of 1 mm/min (fig 7). Fracture was identified when a sudden drop in load was detected by the UTM software, typically accompanied by an audible crack. The test terminated automatically, and the maximum force (in Newtons) required to induce fracture was recorded for each sample.



Fig-7: Samples were subjected to UTM

STATISTICAL STUDY

The Shapiro-Wilk test was performed to evaluate the normality of fracture resistance data in each group. As the data showed non-normal distribution, non-parametric tests were employed for statistical analysis.

The Kruskal-Wallis test was applied to compare the fracture resistance among the three groups. Following a significant Kruskal-Wallis result, pairwise comparisons between groups were performed using the Mann-Whitney U test with Bonferroni correction. A p-value of <0.05 was considered statistically significant. All analyses were performed using SPSS version 22.0.

RESULT

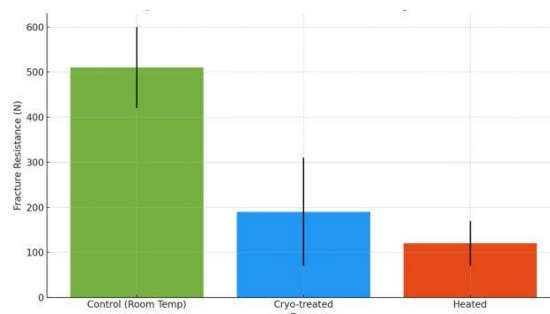
This in vitro study evaluated the effect of sodium hypochlorite (NaOCl) at different temperatures on the fracture resistance of endodontically treated teeth. The samples were divided into three groups based on the irrigation protocol used: Group A (room temperature NaOCl), Group B (cryo-treated

NaOCl at 2.5°C), and Group C (heated NaOCl at 60°C). The fracture resistance values were recorded in Newtons (N).

The below table 1 presents the fracture resistance of endodontically treated teeth irrigated with sodium hypochlorite at different temperatures. Teeth treated with room temperature NaOCl (control group) demonstrated the highest mean fracture resistance (510.79 N). Those treated with cryo-treated NaOCl showed a reduced resistance (226.14 N), while the lowest resistance was observed in teeth treated with heated NaOCl (136.43 N). These findings indicate that temperature variations in sodium hypochlorite, whether cooling or heating, can adversely affect the fracture resistance of endodontically treated teeth.

Table 1: Fracture Resistance of endodontically treated teeth Treated with Different temperature of Sodium Hypochlorite

Group	Sample Size (N)	Mean Fracture Resistance (N)	Standard Deviation (SD)	Statistical Comparison
Control Group (Room Temp NaOCl)	24	510.79	99.27	Reference group
Cryo-treated Sodium Hypochlorite	24	226.14	104.46	Significant vs Control ($p < 0.001$)
Heated Sodium Hypochlorite	24	136.43	54.88	Significant vs Control ($p < 0.001$), Significant vs Cryo ($p = 0.002$)



Graph-1 Comparison Fracture Resistance of Endodontically Treated Teeth

The bar graph below compares the fracture resistance (in Newtons) of endodontically treated teeth across three groups: Control (Room Temperature), Cryo-treated, and Heated. The Control group exhibited the highest fracture resistance, followed by Cryo-treated, with Heated showing the lowest values. Error bars represent the standard deviation, indicating variability within each group.

DISCUSSION

Endodontic irrigation protocols have undergone continuous refinement, with temperature modulation of sodium hypochlorite (NaOCl) emerging as a promising adjunct to enhance its antimicrobial and tissue-dissolving capabilities¹⁰. While elevating the temperature of NaOCl is known to boost its chemical efficacy, the biomechanical implications of such thermal modifications on radicular dentin integrity remain inadequately explored¹¹. This *in vitro* investigation aimed to bridge this knowledge gap by evaluating the effect of heated (60°C) and cryotreated (2.5°C) NaOCl formulations on the fracture resistance of endodontically treated teeth following standardized chemo-mechanical preparation.

The results of the present study demonstrated a statistically significant reduction in fracture resistance in specimens irrigated with heated NaOCl when compared to those treated with cryotreated NaOCl. This finding suggests that irrigant temperature plays a critical role in modulating dentin mechanical properties¹², irrespective of subsequent obturation or coronal restoration¹³. While the enhanced chemical properties of heated NaOCl offer clear advantages in disinfection and tissue dissolution¹⁴, they may come at the cost of structural compromise to the dentin¹⁵.

The increased efficacy of heated NaOCl is well-documented in the literature, with studies attributing its enhanced performance to elevated levels of free chlorine and accelerated reaction kinetics¹⁶. These factors collectively contribute to superior tissue dissolution and microbial eradication¹⁷. However, the increased reactivity also facilitates oxidative degradation of the organic matrix within dentin—particularly the collagen fibrils—which are integral to its viscoelastic properties¹⁸. As a result, dentin becomes more brittle and susceptible to fracture¹⁹.

This deleterious effect of NaOCl on dentin has been previously documented. Marending et al. observed that NaOCl, even at room temperature, significantly diminishes the flexural strength and elasticity of dentin due to collagen depletion¹¹. Furthermore, Sim et al. reported that thermal enhancement of NaOCl intensifies its proteolytic and cytotoxic effects, accelerating deproteinization within the intertubular dentin and resulting in increased embrittlement¹². The present study aligns with these observations, further emphasizing that

while heated NaOCl enhances chemical cleaning¹⁴, it may compromise the structural integrity of root dentin, increasing the risk of vertical root fractures²⁰, particularly in teeth with reduced dentinal thickness²¹.

In contrast, the use of cryotreated NaOCl offers a more conservative and potentially safer approach²². Cooling NaOCl to approximately 2.5°C appears to attenuate its oxidative capacity by slowing down reaction kinetics and reducing the formation of aggressive free radicals¹³. This decrease in chemical reactivity limits the degradation of the organic dentinal components, especially collagen, helping to preserve dentin's structural integrity²³. Supporting this, Vera et al. demonstrated that cold NaOCl caused significantly less dentinal erosion and ultrastructural damage than solutions at room temperature¹⁴. Similarly, De-Deus et al. reported that cold irrigation resulted in smoother dentin surfaces, with less surface roughness and reduced microcrack formation¹⁵.

Consistent with these findings, the present study showed that samples irrigated with cryotreated NaOCl exhibited significantly higher fracture resistance compared to those treated with heated solutions²⁴. This suggests that cryotherapy may help preserve dentinal microarchitecture and mechanical integrity, thus offering a valuable irrigation strategy—particularly in cases where dentin preservation is paramount²⁵.

Maintaining the mechanical strength of radicular dentin is crucial for the long-term prognosis of endodontically treated teeth²⁶. Weakened dentin is more prone to vertical root fractures, especially in teeth restored with posts or those lacking full-coverage restorations²⁷. While heated NaOCl remains advantageous due to its enhanced disinfection potential¹⁶, its use must be judicious, especially in structurally compromised or high-risk teeth²¹.

Cryotherapy, though relatively novel in endodontics, shows significant promise in preserving dentin biomechanics while still offering adequate antimicrobial action¹⁴. Additionally, cold irrigation may reduce post-operative inflammation due to its anti-inflammatory potential²⁸. The encouraging results of this study underscore the clinical relevance of incorporating cryotreated NaOCl into irrigation protocols, especially in patients with delicate or curved roots, elderly individuals, or those with predisposing factors for dentin fragility.

In conclusion, while both thermal modifications of NaOCl have distinct advantages, their clinical use should be tailored based on individual case requirements. Further investigations, including in vivo studies and long-term clinical trials, are warranted to optimize temperature-controlled irrigation strategies and validate their efficacy and safety in diverse clinical scenarios.

CONCLUSION

Within the limitations of this study, it can be concluded that the temperature of sodium hypochlorite plays a significant role in the fracture resistance of endodontically treated teeth. While room temperature NaOCl preserved the highest fracture resistance, cryo-treated sodium hypochlorite despite reducing fracture resistance compared to the control was less detrimental than heated NaOCl. Given its known benefits such as enhanced tissue dissolution and antimicrobial efficacy, cryo-treated NaOCl may offer a balanced approach by improving disinfection while minimizing the adverse effects on root dentin strength compared to heated NaOCl.

REFERENCES

1. Siqueira JF Jr, Rôças IN. Clinical implications and microbiology of bacterial persistence after treatment procedures. *J Endod.* 2008;34(11):1291–1301.
2. Ng YL, Mann V, Gulabivala K. Outcome of secondary root canal treatment: a systematic review of the literature. *Int Endod J.* 2008;41(12):1026–46.
3. Wu MK, Wesselink PR. A primary observation on the preparation and obturation of oval canals. *Int Endod J.* 2001;34(2):137–41.
4. Shahravan A, Haghdoust AA, Adl A, Rahimi H, Shadifar F. Effect of smear layer on sealing ability of canal obturation: a systematic review and meta-analysis. *J Endod.* 2007;33(2):96–105.
5. Gomes BPFA, Ferraz CCR, Vianna ME, et al. In vitro antimicrobial activity of several concentrations of sodium hypochlorite and chlorhexidine gluconate in the elimination of *Enterococcus faecalis*. *Int Endod J.* 2001;34(6):424–8.
6. van der Sluis LW, Versluis M, Wu MK, Wesselink PR. Passive ultrasonic irrigation of the root canal: a review of the literature. *Int Endod J.* 2007;40(6):415–26.
7. Cunningham WT, Balekjian AY. Effect of temperature on collagen-dissolving ability of sodium hypochlorite endodontic irrigant. *Oral Surg Oral Med Oral Pathol.* 1980;49(2):175–7.
8. Al-Nahlawi T, Doumani M, Al-Shurafa S, Shurrah H. Evaluation of postoperative pain following root canal therapy using warm and cold NaOCl: a randomized clinical study. *Saudi Endod J.* 2018;8(2):77–82.
9. Metzger Z. Disinfection of the root canal system: The use of “active” irrigation techniques. *Dent Clin North Am.* 2010;54(2):471–91.
10. Sirtes G, Waltimo T, Schaetzle M, Zehnder M. The effects of temperature on sodium hypochlorite short-term stability, pulp dissolution capacity, and antimicrobial efficacy. *J Endod.* 2005;31(9):669–71.
11. Marending M, Paqué F, Fischer J, Zehnder M. Impact of irrigant sequence on mechanical properties of human root dentin. *J Endod.* 2007;33(11):1325–8.
12. Sim TP, Knowles JC, Ng YL, Shelton J, Gulabivala K. Effect of sodium hypochlorite on mechanical properties of dentine and tooth surface strain. *Int Endod J.* 2001;34(2):120–32.
13. De-Deus G, Souza EM, Marins JR, Reis C, Paciornik S, Zehnder M. Smear layer dissolution and dentinal tubule disinfection induced by different irrigation protocols. *J Endod.* 2011;37(8):1236–40.
14. Vera J, Arias A, Romero M. Dynamic movement of warm and cold sodium hypochlorite in a closed canal system. *J Endod.* 2015;41(12):1934–8.
15. De-Souza LC, De-Deus G, Canabarro A, et al. Dentinal surface alterations promoted by different irrigant solutions: a SEM study. *Microsc Res Tech.* 2018;81(3):235–40.
16. Gordon TM, Damiano T. Temperature-induced changes in sodium hypochlorite solutions. *J Endod.* 2004;30(4):220–1.
17. Hand RE, Smith ML, Harrison JW. Analysis of the effect of dilution on the necrotic tissue

dissolution property of sodium hypochlorite. *J Endod.* 1978;4(2):60-4.

18. Okino LA, Siqueira EL, Lopes HP, Santos M. Influence of the frequency of sodium hypochlorite renewal on its capacity to dissolve pulp tissue. *Int Endod J.* 2004;37(5):380-5.

19. Grigoratos D, Knowles J, Ng YL, Gulabivala K. Effect of exposing dentine to sodium hypochlorite and calcium hydroxide on its flexural strength and elastic modulus. *Int Endod J.* 2001;34(2):113-9.

20. Plotino G, Grande NM, Mercade M, et al. Influence of different sodium hypochlorite concentrations on dentinal damage after root canal irrigation. *J Endod.* 2019;45(6):786-90.

21. Huang FM, Tai KW, Chou MY, Chang YC. Cytotoxicity of sodium hypochlorite on human periodontal ligament cells and its protection by ascorbic acid. *J Formos Med Assoc.* 2001;100(11):748-53.

22. Pasqualini D, Mollo L, Scotti N, et al. Postoperative pain after manual and mechanical glide path: a randomized clinical trial. *J Endod.* 2012;38(1):32-6.

23. Zehnder M. Root canal irrigants. *J Endod.* 2006;32(5):389-98.

24. Boutsoukias C, Verhaagen B, Versluis M, et al. Evaluation of irrigant flow in the root canal using different needle types by an unsteady computational fluid dynamics model. *Int Endod J.* 2010;43(10):874-81.

25. Kim HC, Kim HJ, Lee CJ, et al. Microcrack formation during instrumentation by different nickel–titanium files and micro-computed tomography evaluation. *Scanned Microsc.* 2015;39(2):70-5.

26. Zand V, Mokhtari H, Hasani A, et al. Fracture resistance of endodontically treated roots using a new resin-based root canal filling material. *Iran Endod J.* 2014;9(3):187-90.

27. Assif D, Gorfil C. Biomechanical considerations in restoring endodontically treated teeth. *J Prosthet Dent.* 1994;71(6):565-7.

28. Keskin C, Gülsoy M, Sönmez G. The effect of different irrigation protocols on postoperative pain

and healing after endodontic treatment: A randomized clinical trial. *Clin Oral Investig.* 2018;22(1):301-11.

29. Peters OA. Current challenges and concepts in the preparation of root canal systems: a review. *J Endod.* 2004;30(8):559-67.

To Compare Outcome Of Open Reduction & Internal Fixation In Anterior Mandibular Fracture By Use Of Lag Screws And Miniplates - An In Vivo Study

Abstract

Introduction: Anterior mandibular fractures, particularly those involving the symphysis and parasymphysis, are frequently encountered due to road traffic accidents, falls, and assaults. Open reduction and internal fixation (ORIF) using miniplates is widely practiced; however, lag screw fixation has been proposed as a biomechanically superior alternative offering better compression and reduced hardware. This study aimed to compare the clinical outcomes of lag screw versus miniplate fixation in anterior mandibular fractures.

Materials and Methods: A prospective, randomized comparative study was conducted over 2.5 years at the Department of Oral and Maxillofacial Surgery, Mithila Minority Dental College and Hospital, Darbhanga. Twenty-two patients aged 18–67 years with non-comminuted symphysis or parasymphysis fractures were randomized into two equal groups (n=11): Group A (lag screws) and Group B (miniplates). All procedures were performed via an intraoral vestibular approach. Patients were followed clinically and radiographically at baseline, immediately postoperatively, and during the 1st, 3rd, 6th, and 12th postoperative weeks. Parameters analyzed included operative time, fracture gap reduction, postoperative complications, and biting efficiency. Statistical analysis was performed using SPSS version 25.0.

Results: The mean operative time was slightly longer in the lag screw group (52.72 ± 3.95 minutes) compared to the miniplate group (50.18 ± 4.17 minutes), though this was not statistically significant ($p=0.157$). Postoperative fracture gap measurements at points A, B, and C were significantly smaller in the lag screw group ($p<0.05$), indicating better interfragmentary compression. No postoperative complications, such as non-union, infection, or neurosensory deficits, were observed in either group. By the 12th postoperative week, 72.7% of lag screw and 63.6% of miniplate patients resumed normal mastication, with no significant difference ($p=0.647$).

Conclusion: Both fixation methods proved clinically effective with minimal complications. Lag screws demonstrated superior biomechanical stability through better fracture gap reduction, while miniplates offered marginally quicker operative times. Larger studies with extended follow-up are needed to validate these findings for broader clinical implementation.

Dr. Anjani Kumar Jha¹
Dr. Tauseef Fazal²
Dr. Shahid Eqbal³
Dr. Vivek Kumar⁴
Dr. Ashiq Hussan Ansari⁵
Dr. Akash Ganguly⁵

*jha.anjanikumar235@gmail.com*¹
*shahide61@gmail.com*³

Department of Oral and Maxillofacial Surgery.^{1,2,3,4,5}
*Prof. and H.O.D.*¹
*Reader.*²
*Post Graduate Trainee.*³
*Professor*⁴
*Senior lecturer.*⁵

Mithila Minority Dental College and Hospital, Darbhanga, Bihar.^{1,2,3,4,5}

Corresponding Author

Dr. Shahid Eqbal

PGT, Department of Oral and Maxillofacial Surgery, Mithila Minority Dental College and Hospital, Darbhanga

Email: shahide61@gmail.com

INTRODUCTION

The mandible and maxilla form the structural foundation of the facial skeleton and play critical roles in mastication, speech, and aesthetics. Due to their prominent anatomical location, they are particularly prone to trauma, with mandibular fractures being the second most common facial fractures after nasal bone fractures [1,2]. Road traffic accidents (RTAs), falls, assaults, and industrial injuries are the leading causes, with RTAs being most prevalent worldwide [2].

Management of mandibular fractures has evolved from closed techniques like intermaxillary fixation (IMF) to open reduction and internal fixation (ORIF), which allows for early functional recovery and precise anatomical alignment [3]. This shift is supported by biomechanical evidence favoring rigid fixation for improved healing and fewer complications [4].

The introduction of miniplate osteosynthesis by Champy et al. [3] was a significant advancement in mandibular trauma care. Based on ideal lines of osteosynthesis, this technique offers several advantages, including ease of application and the avoidance of external incisions. However, complications such as infection, plate exposure, malunion, and nerve injury have been reported, prompting continued evaluation of alternative methods [5,6].

Lag screw fixation, introduced by Brons and Boering and later refined by Niederdellman et al., provides a biomechanically sound, cost-effective fixation method, particularly in oblique anterior mandibular fractures [2,4]. When executed correctly, lag screws offer outcomes comparable to or better than miniplates in terms of rigidity, stability, and reduced hardware use [2,7].

Despite these advantages, lag screw fixation remains underutilized in some regions, including India, possibly due to limited equipment availability and unfamiliarity with the technique among surgeons [1]. With ongoing debate over the optimal fixation method for anterior mandibular fractures, a comparative evaluation of lag screws and miniplates remains clinically pertinent.

This study aims to compare the outcomes of ORIF using lag screws versus miniplates in anterior mandibular fractures, focusing on stability,

complications, functional recovery, and cost-effectiveness.

MATERIALS AND METHOD

Study Design and Setting

A prospective, randomized comparative study was conducted in the Department of Oral and Maxillofacial Surgery at Mithila Minority Dental College and Hospital, Darbhanga, Bihar, over a period of 2.5 years. Ethical approval was obtained from the Institutional Ethical Committee prior to initiating the study.

Patient Selection

A total of 22 patients aged between 18 and 67 years with anterior mandibular fractures (symphysis and parasymphysis) were enrolled based on the following inclusion and exclusion criteria.

Inclusion Criteria:

- Patients aged 18 to 67 years.
- Non-comminuted fractures of the mandibular symphysis or parasymphysis.
- Medically fit for surgery under local or general anesthesia.
- Willing to provide informed consent and comply with follow-up visits.

Exclusion Criteria:

- Comminuted mandibular fractures.
- Medically compromised patients affecting bone healing.
- Patients unwilling to participate or unfit for surgery.

Randomization and Group Allocation

Patients were randomly divided into two equal groups (n = 11 each) using simple randomization:

- **Group A:** Treated with lag screw fixation (Fig.1. Fig. 2)

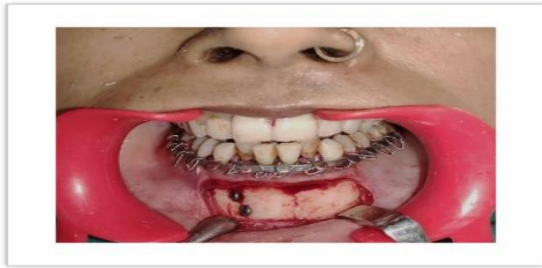

Fig-1: Placement of lag screws

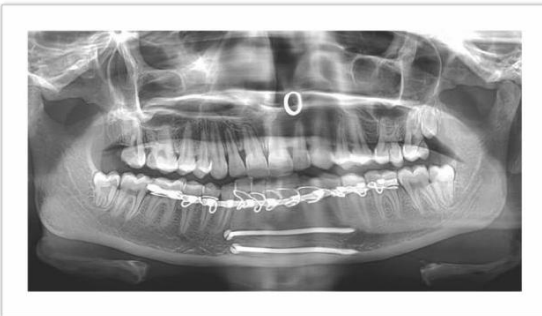

Fig-2: Post-op OPG of lag screw placement.

- **Group B:** Treated with miniplate fixation (Fig.3. Fig. 4)

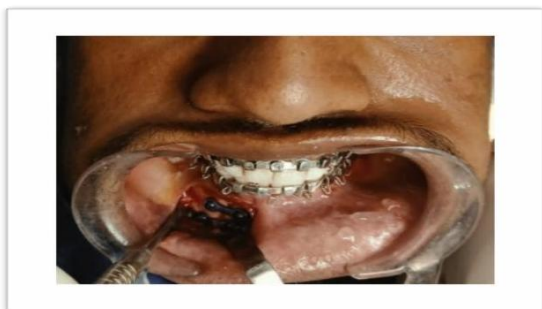

Fig-3: Placement of miniplates.

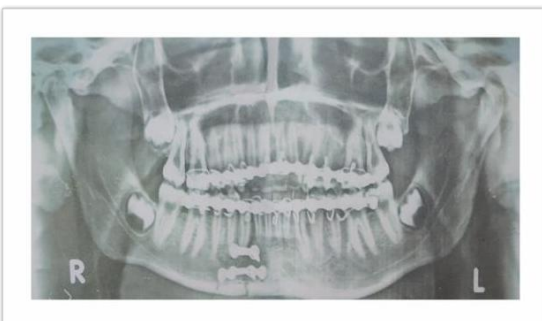


Fig-4: Post-op OPG of miniplate placement.

Surgical Procedure

All surgeries were performed under strict aseptic conditions via an intraoral approach using a vestibular incision from canine to canine. After fracture site exposure and debridement, reduction was achieved using bone-holding forceps and intermaxillary fixation (IMF) when necessary. Fixation was completed using either lag screws or miniplates according to group allocation.

Armamentarium

The procedure employed standard surgical tools, including:

- BP Blade No. 15 with handle
- Titanium lag screws (2.0–2.7 mm diameter, 18–24 mm length)
- Miniplates and screws (2.0–2.5 mm plates with 6–8 mm screws)
- Drill bits, countersink tools, screwdrivers, depth gauges
- Non-absorbable sutures (3-0 Vicryl and Mersilk)
- Stopwatch for operative time recording
- Digital vernier caliper for fracture gap assessment

Outcome Measures

Patients were evaluated clinically and radiographically at baseline (preoperative), immediately postoperatively, and at 1st, 3rd, 6th, and 12th postoperative weeks. Data were recorded in a standardized proforma. The following parameters were assessed:

1. **Operative Time:** Measured from incision to closure using a stopwatch.
2. **Fracture Gap:** Evaluated pre- and post-operatively on orthopantomograms using a digital vernier caliper.
3. **Postoperative Complications:** Including infection, hardware failure, sensory disturbances, and union status.
4. **Biting Efficiency:** Assessed using a 4-point scale:

0: Liquid diet only

1: Able to chew semisolid food

2: Able to chew soft food

3: Able to chew normal food

Investigations

Preoperative investigations included complete blood count, bleeding time, clotting time, viral markers, and orthopantomogram. Postoperative evaluation included clinical photographs and follow-up orthopantomograms.

Statistical Analysis

Data collected were entered and analyzed using IBM SPSS Statistics for Windows, Version 25.0 (IBM Corp., Armonk, NY, USA).

RESULT

This randomized clinical in vivo study included 22 patients with anterior mandibular fractures who were randomly divided into two equal groups: Group A (n=11) treated with lag screws, and Group B (n=11) treated with miniplates. The study evaluated and compared the outcome parameters, including age, gender, operative time, fracture gap, post-operative complications, and biting efficiency over a 12-week period.

The mean age in Group A was 31.90 ± 13.87 years and in Group B was 22.54 ± 3.53 years. The inter-group difference in age was statistically non-significant ($p = .157$) (Table 1).

Group	Mean Age (years)	T value	p-value
Group A	31.90 ± 13.87	1.470	.157
Group B	22.54 ± 3.53		

The mean operative time in Group A was 52.72 ± 3.95 minutes and in Group B was 50.18 ± 4.17 minutes. The difference was not statistically significant ($p = .157$) (Table 2).

Group	Operative Time (minutes)	T value	p-value
Group A	52.72 ± 3.95	1.470	.157
Group B	50.18 ± 4.17		

Post-operatively, gap measurements at Points A, B, and C were significantly greater in Group A than Group B ($p < .05$), while differences at Point D were not significant (Table 3).

Point	Group A (mm)	Group B (mm)	T value	p-value
A	0.70 ± 0.51	0.36 ± 0.15	2.144	.044*
B	0.55 ± 0.29	0.23 ± 0.12	3.349	.003*
C	0.43 ± 0.34	0.18 ± 0.08	2.415	.025*
D	0.31 ± 0.31	0.16 ± 0.05	1.653	.114

There were no post-operative complications observed in either Group A or Group B throughout the study period (Table 4).

Complication	Group A (n=11)	Group B (n=11)	Total (n=22)
Non-union	0 (0.0%)	0 (0.0%)	0 (0.0%)
Delayed union	0 (0.0%)	0 (0.0%)	0 (0.0%)
Hypoesthesia	0 (0.0%)	0 (0.0%)	0 (0.0%)
Paraesthesia	0 (0.0%)	0 (0.0%)	0 (0.0%)

At the 12th postoperative week, 72.7% of Group A and 63.6% of Group B participants could chew normal food. This difference was statistically non-significant ($p = .647$) (Table 5).

Type of Diet (12th Week)	Group A (n=11)	Group B (n=11)	Total (n=22)
Soft food	3 (27.3%)	4 (36.4%)	7 (31.8%)
Normal food	8 (72.7%)	7 (63.6%)	15 (68.2%)

DISCUSSION

This prospective study compared ORIF using lag screws versus miniplates in 22 patients with anterior (symphysis/parasymphysis) mandibular fractures. The male predominance (94%) aligns with previous findings by Ellis and Ghali [8] and Killey & Kay [9], likely due to higher-risk exposure in this demographic. Isolated symphysis fractures (56%) predominated, consistent with Vassallo et al.'s classification of mandibular fracture patterns [10].

Operative duration was slightly longer for lag screws (52.7 ± 3.95 min) than for miniplates (50.2 ± 4.17 min), though not statistically

significant. Similar findings were reported by Goyal et al. [11] and Elhussein et al. [12], attributing the difference to the technical precision required for parallelism in lag screw placement. A marginally shorter procedural time with miniplates may contribute to reduced anesthesia exposure and hospitalization [11,13,10].

Significantly lower fracture-gaps at points A–C were observed in the lag-screw group postoperatively, reflecting interfragmentary compression. This supports biomechanical studies by Madsen et al. [14] and Fordyce et al. [15], which highlight the superior rigidity achieved via lag screw fixation. Similar clinical results were seen in studies by Agnihotri et al. [16], Bhatnagar et al. [17], and Schnäf et al. [18]. The significant improvement at the lower border (point D) further confirms the efficacy of compression osteosynthesis using lag screws.

Neither group experienced non-union, infection, or hardware failure in this study. This aligns with reported low complication rates in lag screw fixation by Tiwana et al. [19] and Haranal et al. [20]. Plate fixation complications described in literature—such as exposure, infection, and malunion [21,22]—were not encountered here, likely due to proper surgical technique, patient selection, and the small sample size.

Both groups demonstrated comparable improvements in masticatory efficiency, with most patients consuming soft food by week 3 and returning to a normal diet by week 12. These functional gains mirror the findings of Jadwani et al. [23] and Mishra et al. [24], who reported no significant dietary variance between fixation techniques.

Although the sample size was small ($n = 22$), the study was adequately powered to detect differences in gap reduction. Longer-term follow-up could offer better insight into neurosensory recovery and late complications. Future studies with larger cohorts and multicentric designs are encouraged.

CONCLUSION

In conclusion, this comparative study between lag screw and miniplate fixation techniques in anterior

mandibular fractures reveals that both methods are effective in achieving stable fixation, early functional recovery, and minimal postoperative

complications. Lag screw fixation, in particular, showed better interfragmentary compression and smaller postoperative fracture gaps, indicating superior biomechanical stability. Miniplate fixation, however, offered slightly reduced operative time, making it a practical option in clinical settings. Despite these encouraging results, the current sample size and follow-up duration limit the generalizability of the findings. A study with a greater sample size and longer follow-up is required for more definitive conclusions and wider clinical application.

REFERENCES

1. Kale TP, Baliga SD, Ahuja N, Kotrashetti SM. A comparative study between transbuccal and extra-oral approaches in treatment of mandibular fractures. *J Maxillofac Oral Surg*. 2010;9(1):9–12.
2. Agnihotri A, Prabhu S, Thomas S. A comparative analysis of the efficacy of cortical screws as lag screws and miniplates for internal fixation of mandibular symphyseal region fractures: a randomized prospective study. *Int J Oral Maxillofac Surg*. 2014;43(1):22–8.
3. Champy M, Loddé JP, Schmitt R, Jaeger JH, Muster D. Mandibular osteosynthesis by miniature screwed plates via a buccal approach. *J Maxillofac Surg*. 1978;6(1):14–21.
4. Niederdelman R, Smith J, Johnson M. Treatment of mandibular fractures: A review of current techniques. *J Oral Maxillofac Surg*. 45(2):123–130.
5. Rudderman RH, Mullen RL, Phillips JH. The biophysics of mandibular fractures: an evolution toward understanding. *Plast Reconstr Surg*. 2008;121(2):596–607.
6. Kuriakose MA. A review of 266 mandibular fractures with internal fixation using rigid AO/ASIF plates or mini-plates. *J Oral Maxillofac Surg*. 1966;24(3):123–131.
7. Ellis E, Ghali GE. Mandibular fractures: Treatment and management strategies. *J Oral Maxillofac Surg*. 1991;49(5):456–463.
8. Ellis E, Ghali GE. Mandibular fractures: Treatment and management strategies. *J Oral Maxillofac Surg*. 1991;49(5):456–463.

9. Killey HC, Kay LW. Fractures of the Mandible. Wright, London; 1969.
10. Vassallo P, Palmer J, Tiong G. Epidemiology, classification, and treatment strategies for mandibular fractures. *J Craniofac Surg.* 2011;22(4):1376–1382.
11. Goyal M, et al. Comparative evaluation of fixation techniques in anterior mandibular fractures... *J Oral Maxillofac Surg.* 2012;70(8):1742–1747.
12. Elhoussein MS, et al. Comparison of outcomes using cortical lag screws versus miniplates... *J Oral Maxillofac Surg.* 2017;75(6):1234–1239.
13. Mohammed AA, et al. Effect of the shape of miniplate on stability of mandibular fractures. *J Craniomaxillofac Surg.* 2017;45(8):1345–1350.
14. Madsen MJ, et al. A biomechanical evaluation of plating techniques used for reconstructing mandibular symphysis/parasymphysis fractures. *J Craniomaxillofac Surg.* 2008;36(8):440–445.
15. Fordyce AM, Lalani Z, Songra AK, Hildreth AJ, Carton AT, Hawkesford JE. Intermaxillary fixation is not usually necessary to reduce mandibular fractures. *Br J Oral Maxillofac Surg.* 1999;37(1):52–57.
16. Agnihotri A, Agnihotri D. Comparative evaluation of lag screws and miniplates in anterior mandibular fracture fixation. *J Maxillofac Oral Surg.* 2010;9(1):3–8.
17. Bhatnagar A, et al. Comparative analysis of osteosynthesis of mandibular anterior fractures... *J Oral Maxillofac Surg.* 2012;70(7):451–456.
18. Schnäf E, et al. Clinical evaluation of lag screw versus miniplate osteosynthesis in mandibular fractures. *J Oral Surg.* 2010;68(9):1203–1209.
19. Tiwana PS, et al. Lag screw fixation of anterior mandibular fractures. *J Oral Maxillofac Surg.* 2007;65(9):1750–1756.
20. Haranal SR, et al. Titanium lag screw osteosynthesis in the management of mandibular fractures. *J Craniomaxillofac Surg.* 2012;40(3):254–258.
21. Alpert B, Tiwana PS. Complications in mandibular trauma: Hardware failure and infection. *Oral Maxillofac Surg Clin N Am.* 2007;19(1):71–78.
22. Mehra P, Murad H. Complications of mandibular fractures. *Oral Maxillofac Surg Clin N Am.* 2007;19(1):109–122.
23. Jadwani S, et al. A new minimal access technique for management of anterior mandible fracture... *J Oral Maxillofac Surg.* 2011;69(4):220–225.
24. Mishra N, et al. Comparative study on masticatory efficiency... *J Oral Maxillofac Surg.* 2020;78(6):1084–1090.
25. Singh V, Bhagol A, Goel M. Management of mandibular fractures: Clinical outcomes of different fixation methods. *Natl J Maxillofac Surg.* 2013;4(1):25–30.

Comparative Evaluation of the Impact of Bioactive Glass and Its Combination with Proanthocyanidin on Apical Microleakage of Root End Filling Material: A Confocal Laser Scanning Microscope Study

Abstract

Objective: This invitro study was conducted to assess the effect of Bioactive Glass and Its Combination with Proanthocyanidin on Apical Microleakage of Root End Filling Material.

Materials and Methods: Thirty female Subjects within age Forty-five single-rooted premolars were cleaned, autoclaved, and underwent root canal treatment. The teeth were decoronated to standardize the root length to 14 mm, with the coronal end of root canal sealed using flowable composite after proper cleaning, shaping and obturation. A 3 mm apical resection was performed, and root-end cavities were prepared with ultrasonic tips and the samples were divided into three groups (n=15):

- Group A (no pretreatment before MTA placement),
- Group B (Bioactive Glass pretreatment before MTA), and
- Group C (Bioactive Glass + 6.5% Proanthocyanidin pretreatment before MTA).

Following pretreatment and root-end filling in the respective groups, the samples were coated with nail varnish—excluding the prepared cavity—to prevent microleakage. They were then dried, immersed in 2% rhodamine B dye for 24 hours, sectioned buccolingually, and examined for apical dye penetration using a confocal laser scanning microscope at 40× magnification

Results: Horizontal parameters shows a statistically significant Group C showed minimum apical dye penetration ($29.57 \pm 3.21 \mu\text{m}$), followed by Group B ($33.11 \pm 3.79 \mu\text{m}$). The maximum apical dye penetration was observed in Group A ($51.95 \pm 3.73 \mu\text{m}$).

Conclusion: Pretreatment agents significantly improved the sealing ability of root-end filling material by enhancing bonding to dentin through collagen cross-linking, which stabilizes exposed collagen, promotes mineral deposition, thus preventing bacterial infiltration over time. Combination of Proanthocyanidin and Bioactive Glass demonstrated a synergistic effect. This resulted in superior dentin stabilization and a more effective apical seal, essential for the long-term success of endodontic therapy.

Keywords: Apical microleakage; Bioactive Glass; MTA ; Periradicular Surgery; Proanthocyanidin.

Dr. Harpreet Singh Chhabra¹

Dr. Ikshita Deshwal²

Dr. Sanjeev Kumar Srivastava³

Dr. Kshiti Bhardwaj⁴

Dr. Aditya Singh⁵

Dr. Preeti Rastogi⁶

harryagar@gmail.com¹

ikshi756@gmail.com²

sanjeevsrivastava409@gmail.com³

drkshitchhabra@gmail.com⁴

aditya.revisited1989@gmail.com⁵

anuradharstg@gmail.com⁶

*Department of Conservative Dentistry
and Endodontics.^{1,2,3,4,5,6}*

Post Graduate Trainee.²

Prof. and MDS.^{1,3,4}

Reader.⁵

Senior lecturer.⁶

*Sardar Patel Post Graduate Institute of
Dental and Medical Sciences, Lucknow,
Uttar Pradesh, India.^{1,2,3,4,5,6}*

Corresponding Author

Dr. Harpreet Singh Chhabra

*Sardar Patel Post Graduate Institute of Dental
and Medical Sciences, Lucknow, Uttar Pradesh,
India*

Email: *harryagar@gmail.com*

INTRODUCTION

Standard endodontic treatment aims to eliminate bacterial infection and establish a fluid-tight hermetic seal to prevent re contamination. Success of the endodontic therapy relies on proper cleaning, shaping, and sealing of the root canal system¹. A compromised apical seal permit microorganisms and toxins to migrate through the apex, lateral canals, and ramifications, while an effective coronal seal blocks microbial and debris entry from the oral cavity².

When nonsurgical endodontic treatment fails, surgical intervention i.e, typically root end resection followed by root-end filling— is necessary. It is indicated in root canals with complex anatomy, calcifications, granulomas or cysts, resorption of root, or open apices. In open apex cases, root end filling help in formation of a calcific barrier which prevent bacterial ingress³. The ideal root end filling material should be biocompatible, dimensionally stable, and adhere well to cavity walls. Mineral Trioxide Aggregate³ (MTA) is preferred due to its high pH, osteo-inductive nature, and its potential to set in the moist conditions⁴.

Irrigation plays an important role in disinfecting and removing the debris. Sodium hypochlorite (NaOCl) is gold standard because of the antimicrobial and tissue-dissolving abilities. However, its proteolytic activity can degrade dentinal collagen, weakening canal walls. EDTA, a chelating agent, is used alongside NaOCl to remove the smear layer by demineralizing inorganic dentin. Yet, their sequential use can result in the softening of dentin, which makes it more susceptible to the damage and affects the quality of root end preparation⁵.

To address the drawbacks, pre-treatment with remineralizing and cross linking agents is suggested. Proanthocyanidin (PA) is a polyphenolic bioflavonoid compound which strengthens the dentin by cross linking collagen, enhancing the resistance to degradation, and promoting mineral deposition⁶. Bioactive Glass (BAG) is a silica-based material known for its bioactivity and ability to form a hydroxycarbonate apatite (HCA) layer. It supports in remineralization, exhibit osteoinductive nature and antibacterial properties, also it inhibits MMPs to preserve dentin integrity⁷.

Microleakage remains a significant cause of reinfection and endodontic treatment failure.

Therefore, evaluating the efficacy of pretreatment agents in reducing microleakage is essential to enhance long-term treatment outcomes. While several studies have demonstrated individual efficacy of the bioactive glass (BAG) and proanthocyanidin (PA) in decreasing the apical microleakage, but their synergistic effect remains unexplored. Therefore, this study aims to evaluate the impact of a combined BAG and PA pretreatment on the apical microleakage of root-end filling materials.

MATERIALS AND METHOD

Subjects for this study were collected from the Forty-five permanent single-rooted premolars were collected and cleaned using an ultrasonic scaler. Radiographic evaluation was performed, and only fully developed, single-rooted, non-restored teeth with straight roots and a single canal were selected. The teeth were then autoclaved at 121°C under 15 psi pressure for 15 minutes and subsequently stored in distilled water.

The preparation of access cavities was done followed by working length determination with a No. 15 K file and confirmed radiographically. Canals were shaped using ProTaper Gold files up to F3 (ISO size 30/0.09 taper), irrigated with 3% NaOCl and 17% EDTA, and dried using paper points. Obturation was done using gutta-percha and AH Plus sealer via the single-cone technique. Teeth were decoronated at the CEJ to standardize root length to 14 mm. The coronal 3 mm of filling material was removed and sealed with flowable composite.

Samples were then stored in humidifier for seven days. A 3 mm apical resection was performed using a carbide fissure bur. Rootend cavities (3 mm deep) were prepared using ultrasonic tips.

Pretreatment agents were prepared as follows: 20% Bioactive Glass slurry (20 g BAG in 100 mL distilled water) and 6.5% Proanthocyanidin (6.5 g grape seed extract in 100 mL distilled water). Teeth were randomly divided into three groups (n=15):

- **Group A:** No pretreatment before MTA placement
- **Group B:** Root end cavity is pretreated with Bioactive Glass(BAG), followed by MTA
- **Group C:** Root-end cavity pretreated with Bioactive Glass (BAG) + 6.5% Proanthocyanidin, followed by MTA

After the pretreatment and root end filling, two layers of the nail varnish were applied 24 hours later over entire root surface, except the root end filling, and allowed to dry. Samples were immersed in 2% Rhodamine B dye for 24 hours, sectioned longitudinally. The dye penetration is assessed by confocal laser scanning microscope at 40X magnification. Data were recorded and statistically analyzed.

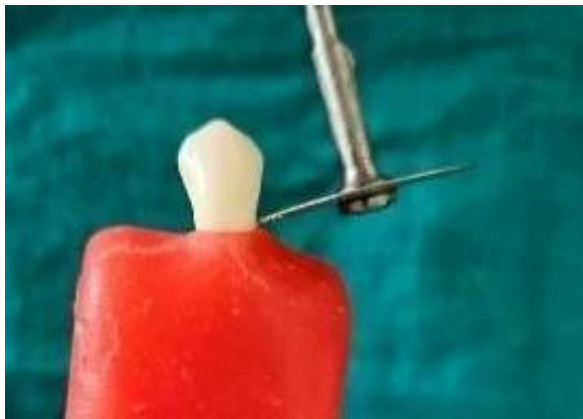

Fig-1: Decoronating the obturated tooth to standardize the root length till 14 mm, followed by coronal sealing of teeth using flowable composite.

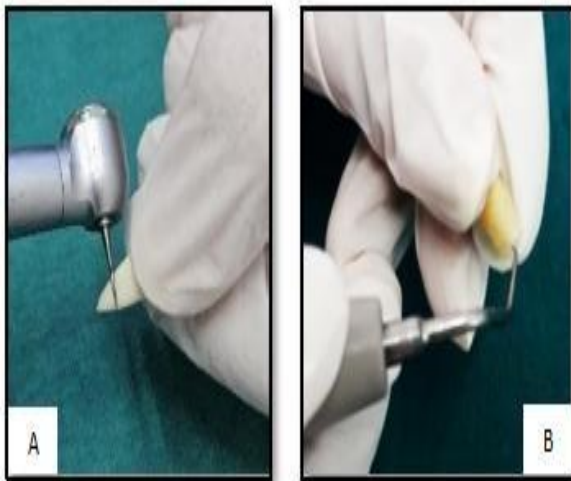


Fig-2: Root end resection and cavity preparation. A- 3mm of root end resection using Tapered fissure carbide bur, B- root end cavity preparation using ultrasonic

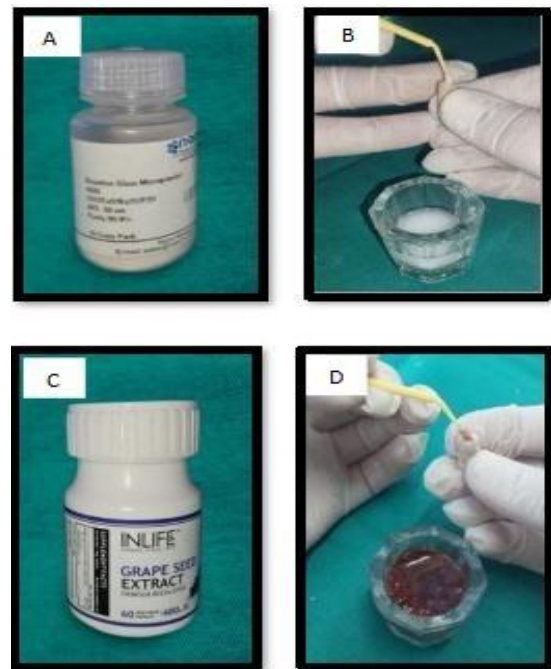


Fig-5: Pretreatment of root end cavity with Bioactive Glass and 6.5 % Proanthocyanidin(Grape seed extract). A- Bioactive Glass, B- Pretreatment of root end cavity with bioactive glass, C- Grape seed extract, D- Pretreatment of root end cavity with grape seed extract

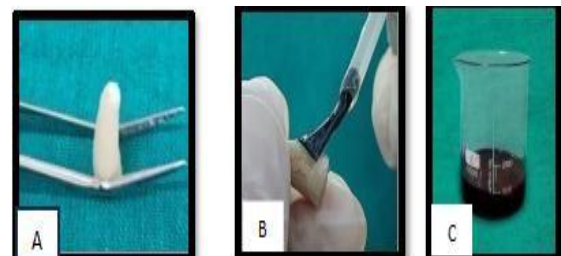
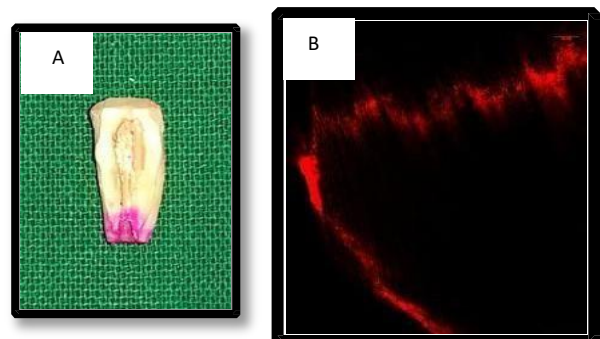


Fig-6: A- Root end filling with MTA, B- application of nail varnish, C- immersion of samples in 2% Rhodamine B dye



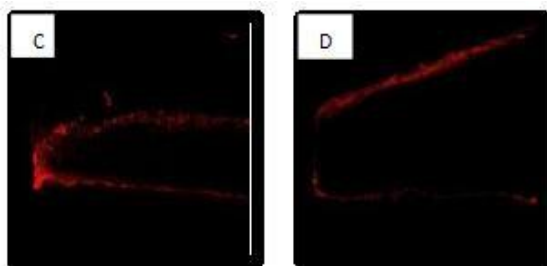


Fig-7: A-Bucco-lingual sectioning of sample, B- CLSM image of apical dye penetration depth in Group A, C- CLSM image of apical dye penetration depth in Group B, D- CLSM image of apical dye penetration depth in Group C at 40X magnification

STATISTICAL ANALYSIS

The data were outlined as Mean \pm SD (standard deviation). Groups were then compared by one factor analysis of variance (ANOVA) and significance of the mean difference between (inter) groups was done by the Tukey's HSD (honestly significant difference) post hoc test after ascertaining the normality by Shapiro-Wilk's test and homogeneity of the variance between the groups by Levene's test. A two- tailed ($\alpha=2$) $P < 0.05$ was considered statistically significant. Analysis was performed on SPSS software version 22.0.

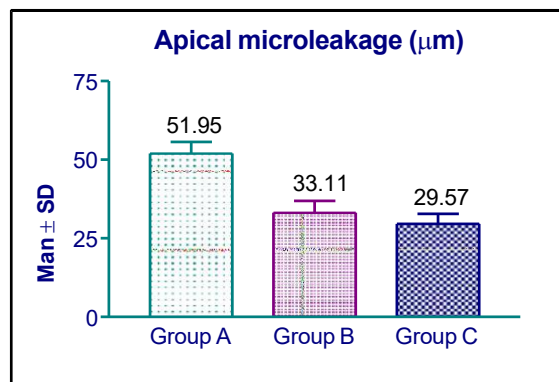
RESULT

The apical microleakage of Group A, Group B and Group C ranged from 46.71-59.32, 28.10-39.09 and 24.08-34.80 μm respectively with mean (\pm SD) 51.95 ± 3.73 , 33.11 ± 3.79 and 29.57 ± 3.21 μm respectively and median 51, 32 and 29 μm respectively. Group C exhibited lowest mean apical microleakage, followed by Group B, while Group A showed the highest. (Group C < Group B < Group A). (Table 1 and Graph.1).

Table 1: Apical microleakage (μm) of three groups

Group	N	Apical microleakage (μm) (Mean \pm SD)	F value	P value
Group A	15	51.95 to 3.73	168.70	<0.001
Group B	15	33.11 to 3.79		
Group C	15	29.57 to 3.21		

Apical microleakage of three groups were summarised in Mean \pm SD and compared by ANOVA (F value)



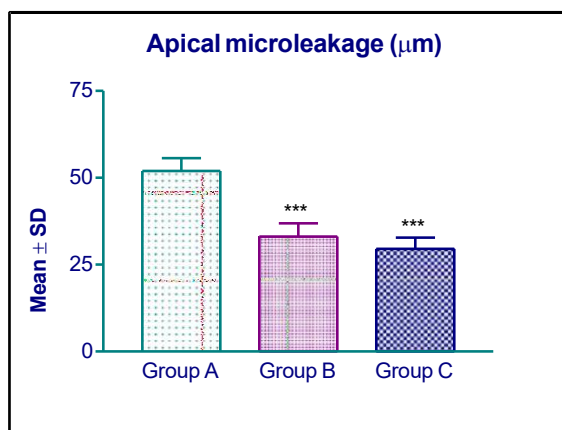
Graph 1: Mean apical microleakage of three groups.

Comparing the mean apical microleakage of three groups, ANOVA showed significantly different apical microleakage among the groups ($F=168.70$, $P < 0.001$) (Table 1). Further, comparing the difference in mean apical microleakage between the groups (i.e. inter groups), Tukey's test depicted significantly lesser apical microleakage in both Group B and Group C as compared to Group A (Table 2 and Graph.2).

Table 2: Comparison of difference in mean apical microleakage (μm) between groups by Tukey test

Comparison	Mean diff.	q value	P value	95% CI of diff.
Group A vs. Group B	18.84	20.34	$P < 0.001$	15.66 to 22.03
Group A vs. Group C	22.38	24.16	$P < 0.001$	19.20 to 25.57
Group B vs. Group C	3.54	3.82	$P < 0.05$	0.35 to 6.72

diff: difference, CI: confidence interval, q value: Tukey test value



* $P < 0.001$ - as compared to Group A

Graph. 2. Comparisons of difference in mean apical microleakage of both Group B and Group C as compared to Group A.

Discussion

Although conventional endodontic treatment has a high success rate of up to 95%, failures still occur in 5–10% of cases, often due to persistent infection, anatomical complexities, cysts, abscesses, or root resorption⁸. Bacterial re-entry or egress of their byproducts leads to failure of endodontic treatment, making a reliable apical seal critical for long-term prognosis. When non-surgical retreatment is unfeasible—such as in calcified canals or persistent symptoms—endodontic surgery becomes necessary. This requires root end resection followed by the placement of root end filling material for achieving an effective apical seal⁹.

Calcium silicate-based materials like MTA and Biodentine are preferred for their osteoinductive and osteoconductive properties, but they lack the chemical bonding to dentin and require some additional measures to ensure the integrity of seal¹⁰. Bharti N et al. (2018) highlighted that dentin's complex structure hinders effective bonding and proposed that pretreatment with crosslinking or remineralizing agents could enhance material adhesion¹¹.

In the present study, pretreatment of root end cavity effectively reduced dye penetration. Group A (root-end filling without pretreatment) showed the highest mean dye penetration depth at 51.95 ± 3.73 µm. Group B (pretreatment with Bioactive Glass) had 33.11 ± 3.79 µm, while Group C (pre-treatment with the combination of Proanthocyanidin and

Bioactive Glass(BAG)) exhibited the lowest dye penetration at 29.57 ± 3.21 µm. This difference indicates that the pretreatment agents improved the adhesion between MTA and dentin in the root-end cavity, likely through collagen crosslinking and the formation of hydroxyapatite structures. These processes contributed to the stabilization of the restoration in the apical area and helped to prevent apical microleakage.

Group A, without any pretreatment, showed highest amounts of apical microleakage. MTA, despite its biological advantages, was less effective in sealing compared to the experimental groups. This was due to handling difficulties, extended setting time and risk of wash-out, which resulted in cement leaching and bacterial leakage¹⁰. Various studies have stated that contamination of unset MTA with tissue fluids deteriorates mechanical properties of the MTA, alters its setting reaction, decreasing formation of crystalline structures of calcium hydroxide. Therefore, exploring additives are added to enhance MTA's performance¹².

Group B, with Bioactive Glass pretreatment, showed less apical microleakage than Group A (no pretreatment). When BAG comes in contact with the dentinal fluid or simulated body fluid, it undergoes surface reactions which results in ion Exchange (sodium (Na^+) and calcium (Ca^{2+}) ions in bioactive glass (BAG) get exchanged with H^+ or H_3O^+ from the fluid surrounding it, increasing the localised pH), formation of the silica gel and deposition of calcium phosphate. Crystallization into the hydroxycarbonate apatite (HCA) (Ca-P layer gradually transforms into HCA, which is chemically and structurally similar to natural tooth mineral). This HCA layer mimics natural tooth mineral, facilitating a bond between the material and dentin, thereby sealing dentinal tubules, and minimizing microleakage¹³.

Group C, in which combination of proanthocyanidin and bioactive glass was used as pretreatment agent, exhibited the least apical microleakage among all groups. This enhances the sealing ability, which is attributed to synergistic effects of both the agents. Proanthocyanidin, interact with the dentin collagen through hydrogen bonding, hydrophobic and covalent interactions, forming insoluble complexes that stabilize the collagen matrix and enhance its mechanical strength¹⁴. According to numerous studies, proanthocyanidin does not initiate mineralization directly, it maintains a scaffold for guided remineralization, facilitating ion deposition from external sources¹⁵.

On the other hand, Bioactive Glass possesses superior remineralization potential due to its high calcium and phosphate content¹⁶. Upon contact with dentinal fluid, BAG releases ions that precipitate as hydroxycarbonate apatite (HCA), forming a biologically active layer that closely mimics natural tooth mineral. BAG produces larger, more angular mineral deposits compared to PA, which creates dense and more adhesive mineral plug and contribute to a better apical seal¹⁶. The combined use of PA and BAG addresses the individual limitations of each agent. The limited intrinsic mineralizing ability of PA is effectively compensated by the robust ion-releasing and mineralizing capacity of BAG. Conversely, the indirect collagen-stabilizing effect of BAG—primarily through inhibition of the matrix metalloproteinases due to increased pH is enhanced by the direct crosslinking action of proanthocyanidin, which reinforces dentin matrix against the biodegradation.

The findings of this study indicate that Group C (combination of Bioactive Glass and Proanthocyanidin as pretreatment) exhibited lowest microleakage which id followed by the Group B (Bioactive Glass pretreatment), with Group A (no pretreatment) depicting highest levels. These finding indicates that pretreatment agents strengthens the collagen fibrils, promotes remineralization, enhances durability of the dentinal bonding, and minimize the risk of cement leaching by reducing the setting time. This, in turn, improves sealing ability of root end filling and help in reduction of probability of the recontamination.

CONCLUSION

This in-vitro study concluded that while all the groups exhibited some amount of apical microleakage, pre-treatment of root end cavity significantly enhanced the sealing ability of the root-end filling material. The pretreatment agents effectively minimized apical microleakage by promoting collagen crosslinking and enhances mineral deposition within the dentin substrate.

The combination of proanthocyanidin and bioactive glass demonstrated synergistic effect, wherein both agents complemented and enhanced the limitations of the other. This resulted in superior dentin stabilization and a more effective apical seal, both of which are required for long term success of the endodontic treatment.

REFERENCES

1. Tait C. Non-surgical endodontics – obturation. *Br Dent J.* 2025;238(5):321–4.
2. Boshnjaku S, Morina J. Coronal microleakage and its impact on the success of endodontic therapy: A narrative review. *Int J Biomed.* 2025;15(2):262–7.
3. Pop I. Endodontic surgery: Part 2. *Br Dent J.* 2013;215(6):279–86.
4. Parirokh M, Torabinejad M. Mineral trioxide aggregate: a comprehensive literature review—Part I: chemical, physical, and antibacterial properties. *J Endod.* 2010;36(2):190–202.
5. Xu QW, Sun HB, Liu YY et al. Effects of concentration of sodium hypochlorite as an endodontic irrigant on the mechanical and structural properties of root dentine: a laboratory study. *Int Endod J.* 2022;55(4):386–394.
6. Liu Y, Chen M, Yao X et al. Enhancement in dentin collagen's biological stability after proanthocyanidins treatment in clinically relevant time periods. *Dent Mater.* 2013;29(4):485–92.
7. Zhang R, Qi J, Gong M, et al. Effects of 45S5 bioactive glass on the remineralization of early carious lesions in deciduous teeth: an in vitro study. *BMC Oral Health.* 2021;21:576.
8. Ho C, Argáez C. Endodontic therapy interventions for root canal failure in permanent dentition: a review of clinical effectiveness, cost-effectiveness, and guidelines. Ottawa (ON): Canadian Agency for Drugs and Technologies in Health (CADTH); 2017 Mar 8. 65 p.
9. Quintero GP, Gil FJ, Gastel C et al. Endodontic procedures for retreatment of periapical lesions. *Int Endod J.* 2017;50(4):314–27.
10. Camilleri J. Biocompatibility and sealing ability of mineral trioxide aggregate and biodentine as root-end filling materials: a systematic review. *Int Endod J.* 2018;51(6):e136–e148.

11. Bharti N, Chandra A, Tikku AP et al. An ex vivo evaluation of effect of dentin pretreatment with various agents for varying time intervals on the shear bond strength of resin. *J Conserv Dent*. 2018;21(1):37–41.
12. Nekoofar MH, Namazikhah MS, Sheykhrezae MS, et al. Effect of blood contamination on the compressive strength of mineral trioxide aggregate. *J Endod*. 2002;28(6): 529–531.
13. Skallefold HE, Rokaya D, Khurshid Z et al. Bioactive Glass Applications in Dentistry. *Int J Mol Sci*. 2019;20(23):5960.
14. Liu Y, Chen M, Yao X, et al. Enhancement in dentin collagen's biological stability after proanthocyanidins treatment in clinically relevant time periods. *Dent Mater*. 2013;29(4):485–92.
15. Zhang Y, Huang Y, Pang Y, et al. Modification of collagen with proanthocyanidins by mimicking the bridging role of glycosaminoglycans for dentine remineralization. *Mater Des*. 2021;210:110067.
16. Manzoor S, Shah SA, Azhar FA et al. Remineralization effect of bioactive glass with and without fluoride and casein phosphopeptide-amorphous calcium phosphate (CPP-ACP) on artificial dentine caries: an in vitro study. *Eur J Dent*. 2024;18(2):385–390.
17. Joshi C, Gohil U, Parekh V et al. Comparative Evaluation of the Remineralizing Potential of Commercially Available Agents on Artificially Demineralized Human Enamel: An In vitro Study. *Contemp Clin Dent*. 2019 ;10(4):605-613.

Management of A C-Shaped Root Canal System: A Case Report

Abstract

Introduction: C-shaped root canal configurations present a significant endodontic challenge due to their complex morphology, which often includes isthmuses, fins, and irregular canal shapes that complicate debridement, shaping, and obturation. This case report describes the endodontic management of a mandibular second molar with a C-shaped canal system identified using clinical and radiographic examination, confirmed by cone-beam computed tomography (CBCT). Access cavity preparation was modified to accommodate the anatomical variation, and meticulous cleaning and shaping were performed using rotary instruments combined with passive ultrasonic irrigation (PUI). To guarantee three-dimensional canal space sealing, obturation was accomplished using the thermoplasticized gutta-percha approach. The patient was followed up postoperatively and demonstrated satisfactory healing both clinically and radiographically. This case highlights the importance of proper diagnosis, individualized treatment planning, and the use of advanced techniques for the successful management of teeth with C-shaped root canal configurations.

Dr. Samiksha¹
Dr. Amit Kumar²
Dr. Ankit Kumar Saha³
Dr. Rajan jha⁴
Dr. Qainaat shaukat⁵
Dr. Rashmi kashyap⁶

Department of Conservative Dentistry and Endodontics.^{1,2,3,4,5,6}

Post Graduate Trainee.^{1,4,5,6}

H.O.D.²

Assistant Professor³

Mithila Minority Dental College and Hospital, Darbhanga, Bihar.^{1,2,3,4,5,6}

Corresponding Author

Dr. Samiksha

Department of Conservative Dentistry and Endodontics, Mithila Minority Dental College and Hospital, Darbhanga, Bihar, India

Email: samikshasaha0@gmail.com

INTRODUCTION

One of the most anatomically difficult and therapeutically challenging endodontic variations is the C-shaped root canal system. Cooke and Cox Firstly reported 1979¹ these morphologies exhibit a characteristic cross-sectional “C” shape. The anomaly is often attributed to the failure of Hertwig’s epithelial root sheath to properly fuse during root development². These configurations typically include fins, isthmuses, and irregular canal patterns that complicate conventional root canal treatment³.

Although mainly found in second mandibular molars, C-shaped canals have been identified in first mandibular molars, maxillary molars, and even premolars, with varying frequencies^{4 5}. Due to their unpredictable and variable internal morphology, C-shaped canals demand advanced diagnostic and management strategies for clinical success⁶.

EPIDEMIOLOGY AND ETIOLOGY

Prevalence studies show a strong ethnic and regional variation in the occurrence of C-shaped canals. Reports from East Asia, particularly China and Korea, show high prevalence in second mandibular molars^{7 8}. Studies from the Middle East, including Iran and Saudi Arabia, report moderate prevalence rates around 13–18%^{9 10}. European and North American populations show much lower prevalence, typically 2.7–7.6%¹¹.

C-shaped canals form due to the incomplete fusion of Hertwig’s epithelial root sheath, especially on the buccal or lingual side. Other contributing factors include genetic predisposition, environmental factors during tooth development, and developmental anomalies such as radicular grooves and taurodontism¹².

ANATOMICAL CLASSIFICATION

3.1 Melton’s Classification¹³

Category I (C1): Continuous C-shaped canal from orifice to apex

Category II (C2): Semicolon-shaped orifice due to discontinuity

Category III (C3): Two or more discrete canals in a fused root

3.2 Fan’s Modified Classification¹⁴

C1: Continuous “C” without separation

C2: Semicolon shape with partial dentin separation

C3: Two or three distinct canals

C4: Single round or oval canal

C5: No visible canal lumen due to classification.

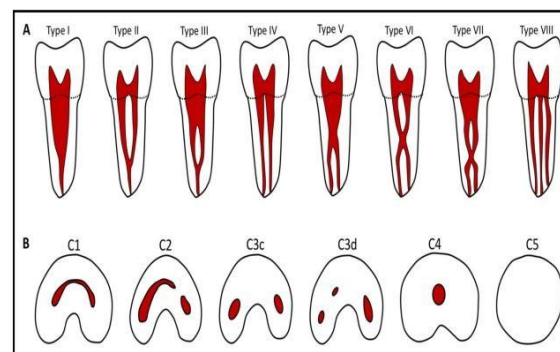


Figure-1

These configurations may change from coronal to apical third. Studies confirm that Consistent morphology along the full length of the root is rare¹⁵¹⁶.

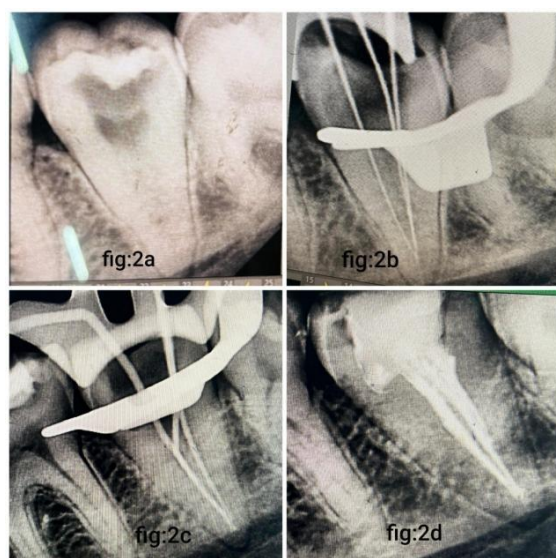CASE REPORT

A 23-year-old male presented to the Department of Conservative Dentistry and Endodontics with a primary complaint of pain while chewing in the lower left posterior region. The patient’s medical history was non-contributory. Clinical examination revealed dental caries involving tooth 37, which was tender on percussion. Radiographic assessment showed an occlusal radiolucency in tooth 37 approximating the pulp chamber, accompanied by periodontal ligament space widening (Figure 2a). The tooth exhibited a conical morphology with fused mesial and distal roots, separated by a faint radiolucent line suggestive of a possible C-shaped canal configuration.

Following adequate anesthesia and rubber dam isolation, an access cavity was established, revealing a C2-type canal anatomy as described by Fan et al. Working length was determined (Figure 2b), and biomechanical preparation was performed with hand K-files (Dentsply Maillefer, Switzerland)

up to size 35. Irrigation was carried out using 5% sodium hypochlorite (Acrylates, India), which was activated with an EndoActivator (Dentsply Maillefer, Switzerland). Calcium hydroxide paste (RC Cal, Prime Dental Products, Thane, India) was placed as an intracanal medicament.

At the one-week recall, the patient was asymptomatic. A radiograph confirmed the master cone adaptation, and obturation was completed with gutta-percha using the Calamus system (Dentsply Maillefer, Switzerland). The access cavity was subsequently restored with composite resin.



DISCUSSION

C-shaped canal configurations represent one of the most complex anatomical variations in root canal systems, particularly within mandibular second molars. Their successful management relies heavily on accurate diagnosis, thorough debridement, and appropriate obturation techniques. The present case report highlights the clinical challenges and procedural considerations specific to a Type 2 C-shaped canal, characterized by a continuous C-shaped configuration from the orifice to the apex¹. Fan et al. later refined this classification using micro-CT analysis, emphasizing five configurations (C1–C5) based on the root cross-section from coronal to apical thirds. Our case corresponds to C1 in Fan's system, where a continuous C-shaped canal is maintained across all levels.⁴

The identification of C-shaped canals can be difficult through conventional radiographs due to superimposition of anatomical structures. Hence, a thorough clinical and radiographic assessment is essential. In our case, the diagnosis was established with the aid of cone-beam computed tomography (CBCT), which provided a detailed three-dimensional representation of the root canal morphology. CBCT has been widely acknowledged for its superior diagnostic accuracy in detecting root canal complexities, including C-shaped canals¹⁷.

Management of C-shaped canals requires modifications to the conventional endodontic approach. Access cavity design plays a crucial role, and in C-shaped configurations, it must be extended buccolingually to expose the isthmus area adequately¹⁸. In the current case, we adopted a conservative yet wide oval-shaped access to facilitate optimal visualization and negotiation of the canal anatomy. Instrumentation of C-shaped canals is inherently difficult due to the presence of fins, webs, and isthmuses that harbor debris and necrotic tissues. Traditional rotary instruments may not effectively contact all canal walls. The use of adaptive file systems such as XP-endo Shaper or SAF (Self-Adjusting File) has shown promise in cleaning irregular morphologies¹⁹. In our case, a hybrid technique incorporating rotary NiTi files and manual instrumentation was employed, supported by ample irrigation to enhance cleaning efficacy.

Irrigation is the cornerstone of debridement in complex canal systems. Given the intricate web-like anatomy of C-shaped canals, effective irrigation becomes paramount. We utilized a combination of sodium hypochlorite and EDTA, supplemented with passive ultrasonic irrigation (PUI). This technique improves irrigant penetration and efficacy, particularly in isthmuses and fins where mechanical instrumentation is limited²⁰. Obturation of C-shaped canals is equally challenging due to the presence of inter-canal communications and late/oral canals. In our case, warm vertical compaction with thermoplasticized gutta-percha was employed, a technique proven effective in adapting to irregular canal morphologies²¹. This method allows better flow of gutta-percha into lateral and accessory canals, reducing the risk of voids. A study by Kim et al. comparing various obturation techniques in C-shaped canals found that warm vertical compaction and injectable thermoplasticized techniques achieved superior

filling quality compared to cold lateral compaction. The use of bioceramic sealers such as EndoSequence BC sealer is also advocated due to their superior flowability and bioactivity, aiding in the sealing of irregular spaces²². The prognosis of teeth with C-shaped canals is generally favorable if meticulous cleaning, shaping, and obturation are achieved. However, the complexity of the anatomy inherently poses a higher risk of missed canals and incomplete debridement, which can compromise outcomes. In the current case, the six-month follow-up demonstrated satisfactory healing, with resolution of clinical symptoms and radiographic evidence of periapical healing.

CONCLUSION

The C-shaped root canal anatomy is very common in mandibular second molars and has an ethnic preference. In order to achieve a good long-term prognosis, successful endodontic care requires accurate diagnosis, solid understanding of aberrant root canal anatomy, and a comprehensive chemomechanical preparation with a 3-dimensional obturation of C-shaped canals.

REFERENCES

1. Cooke HG, Cox FL. C-shaped canal configurations in mandibular molars. *J Am Dent Assoc.* 1979;99(5):836–839.
2. Weine FS. *Endodontic Therapy*. 6th ed. St. Louis: Mosby; 2004.
3. Jafarzadeh H, Wu YN. The C-shaped root canal configuration: a review. *J Endod.* 2007;33(5):517–523.
4. Fan B, Cheung GS, Fan M, Gutmann JL, Bian Z. C-shaped canal system in mandibular second molars: Part I—Anatomical features. *J Endod.* 2004;30(12):899–903.
5. Silva EJ, Nejaim Y, Udrescu DO, Cohenca N. Prevalence and characteristics of C-shaped canals: A CBCT analysis in a Brazilian subpopulation. *Int Endod J.* 2022;55(3):329–336.
6. de Pablo OV, Estevez R, Sánchez MP, Heilborn C, Cohenca N. Root anatomy and canal configuration of the permanent mandibular first molar: A systematic review. *J Endod.* 2010;36(11):1919–1931.
7. Yang ZP, Yang SF, Lee G. C-shaped root canals in mandibular second molars in a Chinese population. *Endo*
8. Jin GC, Lee SJ, Roh BD. Anatomical study of C-shaped canals in mandibular second molars in a Korean population. *J Endod.* 2006;32(1):10–13.
9. Haddad GY, Nehme WB, Ounsi HF. Diagnosis, classification, and frequency of C-shaped canals in mandibular second molars in a Middle Eastern population. *Saudi Dent J.* 2018;30(2):80–86.
10. Al-Fouzan KS. C-shaped root canals in mandibular second molars in a Saudi Arabian population. *Int Endod J.* 2002;35(6):499–504.
11. Ahmed HMA, Dummer PMH. A new system for classifying root and canal anatomy. *Int Endod J.* 2018;51(4):389–426.
12. Gulabivala K, Aung TH, Alavi A, Ng YL. Root and canal morphology of Burmese mandibular molars. *Int Endod J.* 2001;34(5):359–370.
13. Melton DC, Krell KV, Fuller MW. Anatomical and histological features of C-shaped canals in mandibular second molars. *J Endod.* 1991;17(8):384–388.
14. Fan B, Cheung GS, Fan M, Gutmann JL, Bian Z. C-shaped canal system in mandibular second molars: Part II—Radiographic and clinical investigation. *J Endod.* 2004;30(12):904–908.
15. Martins JNR, Marques D, Mata A, Caramês J. Prevalence of C-shaped canal configuration in mandibular molars using cone-beam computed tomography in a Portuguese population. *Int Endod J.* 2018;51(8):881–897.
16. Gu Y, Lu Q, Wang H, Pan Y. CBCT evaluation of C-shaped canals in Chinese mandibular molars: Prevalence, morphology and radiographic features. *Clin Oral Investig.* 2020;24(8):2659–2666
17. Schilder H. Filling root canals in three dimensions. *Dent Clin North Am.* 1967;11(3):723–744.
18. Kwak SW, Ha JH, Cheung GS, Kim HC. Root canal filling quality of a C-shaped canal system with two different thermoplasticized techniques. *Restor Dent Endod.* 2016;41(4):251–256.

19. Wu MK, Wesselink PR, Walton RE. Apical terminus location of root canal treatment procedures. *Oral Surg Oral Med Oral Pathol Oral Radiol Endod.* 2000;89(1):99–103.
20. Siqueira JF, Rôças IN, Favieri A, Lima KC. Chemomechanical reduction of the bacterial population in the root canal after instrumentation and irrigation with NaOCl. *J Endod.* 2002;28(3):181–184.
21. Schilder H. Filling root canals in three dimensions. *Dent Clin North Am.* 1967;11(3):723–744.
22. Koch KA, Brave DG, Nasseh AA. Bioceramic technology: Closing the endo-restorative circle, part II. *Dent Today.* 2010;29(3):82–87.

Radix Entomolaris - A Unique Clinical barrier to Avoid Endodontic Failure: A Case Report

Abstract

Introduction: Radix Entomolaris (RE) is an anatomical variant characterized by the presence of a distolingual supernumerary root, predominantly in mandibular first molars. This variation poses significant endodontic challenges due to its complex morphology and higher prevalence in certain ethnic groups, notably Asian populations. This case report highlights the endodontic management of a 39-year-old male patient presenting with symptomatic irreversible pulpitis in tooth #46. Diagnosis revealed an accessory root and four canal orifices, necessitating modification of access preparation and meticulous biomechanical instrumentation. The use of advanced tools, including apex locators, rotary Ni-Ti files, and three-dimensional obturation techniques, enabled successful treatment. Follow-up demonstrated favorable healing. The discussion emphasizes the need for clinicians to be familiar with RE classifications and identification techniques, such as CBCT and clinical indicators, to avoid missed canals. Early detection and appropriate canal negotiation are vital for long-term prognosis. Awareness of this root morphology enhances treatment outcomes in diverse populations.

Keywords: Radix Endomolaris , Root Canal Faliure

Dr. Sabya Sachi¹

Dr. Ajeet kumar²

Dr. R.K. Divya³

Dr. Amit Kumar⁴

Dr. Rajnish Kumar⁵

Dr. Ankit Kumar Saha⁶

*sachisabya001@gmail.com*¹

Department of Conservative Dentistry and Endodontics.^{1,2,3,4,5,6}

Post Graduate Trainee.^{1,2,3}

*H.O.D.*⁴

*Reader.*⁵

*Senior lecturer.*⁶

Mithila Minority Dental College and Hospital, Lalit Narayan Mithila University, Darbhanga, Bihar.^{1,2,3,4,5,6}

Corresponding Author

Dr. Sabya Sachi

Mithila Minority Dental College & Hospital, Lalit Narayan Mithila University, Darbhanga, Darbhanga, Bihar- 846004, India

Email: *sachisabya001@gmail.com*

INTRODUCTION

According to Carabelli, extra root seen in distolingually of mandibular first molars, is called the radix entomolaris, and extra root found in the mesiobuccal aspect is called the radix paramolaris.⁷ The presence of a supernumerary root in mandibular first molars have been associated with certain ethnic groups. Its reported prevalence is 3.4%–4.2% in Europeans, 3% in Africans, and less than 5% in Eurasian and Indian populations. Among specific groups, the frequency is 4.2% in Europeans, while it ranges from 5% to over 30% in Asians, including Chinese, Eskimos, and American Indians. Additionally, the occurrence has been documented at approximately 1.35% in German patients and around 21% in the Taiwanese population.⁵ Clinicians must be aware of the increased frequency of this anatomical variation in patients of Indian descent while diagnosing and planning the treatment.⁵

The cause behind the formation of radix entomolaris remains unknown, but it may be from extrinsic factors affecting odontogenesis as per Calberson et al. (2007). Another possibility for this may be an expression of some gene deep within the racial genetic factors that lead to more pronounced phenotypic expression.⁸ In addition, the frequent occurrence of fins and interactions among canals within the same root are a hindrance to total disinfection, and the whole treatment process becomes difficult and complex. The presence of confluent canals in the same root can even raise the rate of occurrence of perforations, ledging, and instrument fractures, resulting in failure of treatment.⁹

Proper biomechanical preparation, including irrigation of the canals and three-dimensional filling of a fully prepared root canal, provokes the treatment to prevent the further development of pathology in the periapical region. However, the presence of extra roots may complicate the BMP as well as the obturation of the root canal, compromising the prognosis of RCT.¹ Overlooked canals and inability to eliminate the entire population of micro-organisms with the pulp debris from the root canal system would likely represent the primary cause of chronic infection around endodontically treated molars.⁸

CASE PRESENTATION:

A 39-year-old male patient reported at the

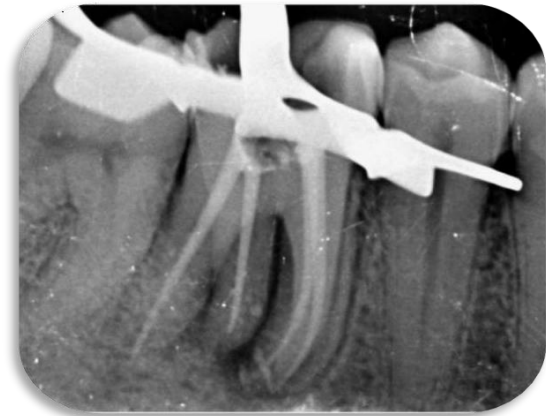
MMDCH, Department of Conservative Dentistry and Endodontics with a chief complaint of pain in the left lower back tooth region since last week. The pain was spontaneous in nature and persisted for minutes after the stimulus (usually heat, less often cold) was removed. The patient had no relevant previous medical & dental history. During intraoral examination, deep occlusal caries was detected wrt #46, which was tender on precision, with vertical bone loss involving furcation, no mobility and swelling was present. On the pulp vitality test, no response was observed. Intra-oral radiograph showed a heterogenous radiolucency of the major coronal portion of the tooth with involvement of pulp, with periapical radiolucency wrt #46. Using the SLOB rule technique, the presence of an accessory root located distally and mesially was confirmed. We have diagnosed symptomatic irreversible pulpitis with symptomatic apical periodontitis wrt #46 (Figure 1) and planned for Root canal treatment followed by crown placement.

The patient received 2% xylocaine with 1:80,000 adrenaline. Rubber dam is placed for proper isolation. Round BR-45 (Mani Inc., Japan) along with Safe End bur EX-24 from the same company were used to prepare the access cavity. When pulp tissue was removed then four orifice was located. Root ZX mini apex locator (J. Morita Corporation, Saitama, Japan) was used to determine the proper working length and cross-checked by doing an angled radiograph (Figure 2). We have used normal saline and sodium hypochlorite protocol. Canal preparation and shaping was done by #25 nickel-titanium (Ni-Ti) rotary files having a 6% taper manufactured by Guilin Woodpecker Medical Instrument Co., Ltd, Guilin, China. The canal was irrigated using 3% sodium hypochlorite (NaOCl) and 0.9% saline alternately. Calcium hydroxide (RC Cal; Prime Dental Products Pvt Ltd, India) and temporary restoration (Neotemp; Orikam Healthcare India Pvt. Ltd, India) was done.

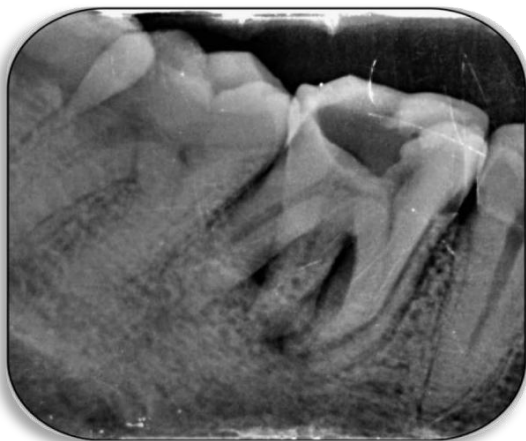The patient is recalled after 7 days for the next appointment, during the intermittent time the patient was asymptomatic. Canals were relocated and activated irrigation protocol was used by ultrasonic activated 17% ethylenediamine tetra-acetic acid (EDTA) to ease extraction of previously deposited intra-canal medicament (water based calcium hydroxide). Final pre-obturation radiograph was taken by placing gutta-percha master cones (Figure 3).

Obturation was performed with the previously measured master cones and oil based sealer (Dia-ProSeal Root Canal Sealer; South Korea). Post-endodontic composite restoration (Spectrum; Dentsply Sirona Inc., Charlotte, North Carolina, United States) was done (Figure 4) followed by crown placement in the further follow-up. (Figure 5).

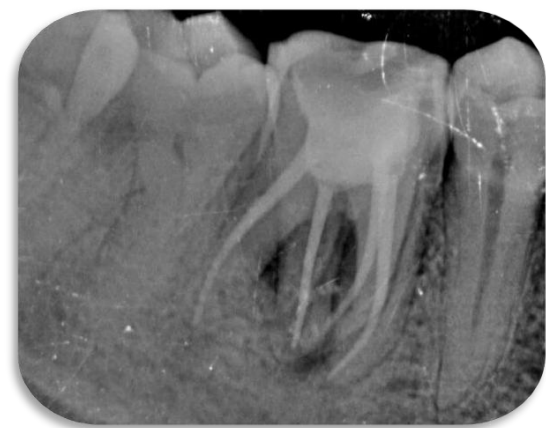At a one-year follow-up, the patient was asymptomatic, and a radiographical decrease in periapical radiolucency was seen. (Figure 6)



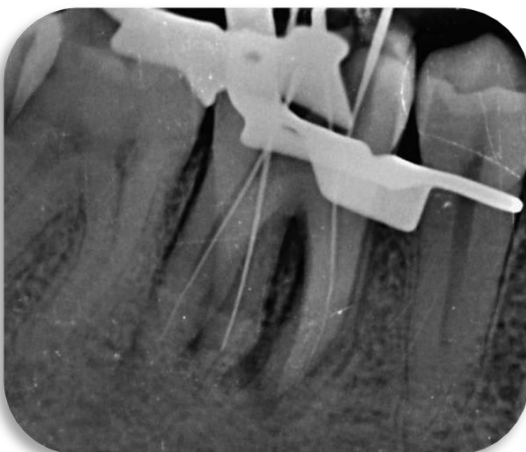
(Figure 3)



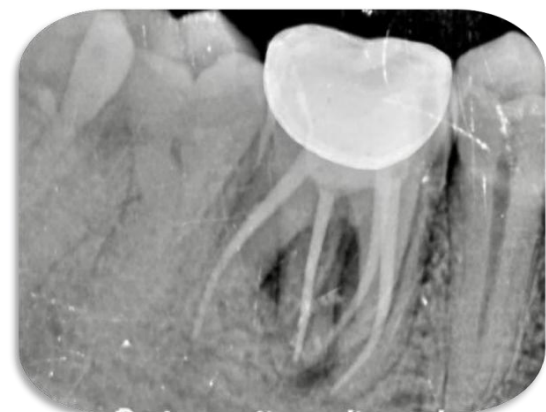(Figure 1)



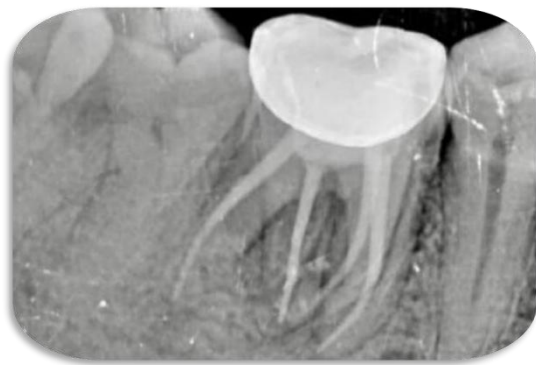(Figure 4)



(Figure 2)



(Figure 5)

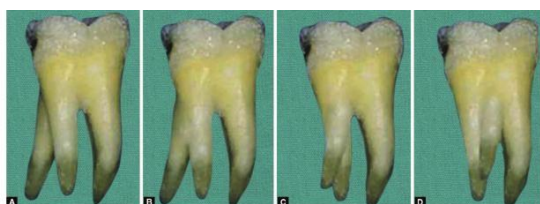


(Figure 5)

DISCUSSION

Carlsen and Alexandersen classified radix entomolaris (RE) in relation to the position of the extra root in cervical region. This system includes types A, B, C, and AC. In Types A and B, the cervical portion is positioned distally, whereas in Type C it is located mesially. Type AC represents a central positioning of the cervical part, lying midway between the mesial and distal root components.

Additionally, De Moor et al. introduced a classification based on the buccolingual curvature of the RE. In this system, Type I represents straight roots and canals; Type II features a curvature in the coronal third near the orifice entrance; and Type III includes two curvatures present each in the coronal and middle thirds of the root.



Figs 6A to D: Carlsen and Alexandersen's classification of RE: (A and B) Showing types A and B that refer to a distally located cervical part of the RE with two normal and one normal distal root components, respectively; (C) Type C refers to a mesially located cervical part; (D) AC refers to a central location between the distal and mesial roots¹⁷

After further canals are identified, the access cavity is required to be altered to better Straight-line access is important in keeping the canal patent, in accurately measuring working length, and in preventing safe canal preparation. This method helps avoid errors such as canal straightening, zipping, strip perforation, incubing instrument fracture, ledging, transportation and strip perforation. Treatment of several intercommunicating canals in the same root is one

of the main endodontic challenges when complete disinfection is the goal and dentin preservation is attempted by minimal canal enlargement. Meeting this challenge needs a sound knowledge of root canal anatomy, coupled with relevant training and clinical skill.

The combination of the latest instruments—i.e., cone-beam computed tomography (CBCT), RVG, magnifying instruments like loupes and dental operating microscopes, efficient exploration methods, biomechanical preparation by different NiTi file systems, and volumetric obturation with three-dimensional compaction by liquid injectable gutta-percha can generously increase the rate of success in such complicated cases.

Existence of an extra cusp, prominent lingual projection, or an eminent convexity in the cervical region may be a marker of the presence of an additional root, which could be key-stone feature in radix entomolaris cases, so clinicians should be aware of that.

CONCLUSION

Recognizing a radix entomolaris before treatment is essential to ensure endodontic success and avoid overlooking canals. If an accessory canal is missed, it may lead to insufficient debridement and elevate the risk of unsuccessful outcomes. Familiarity with the prevalence, anatomical types, and principles for both radiographic and clinical identification of RE facilitates the clinician in tackling its complexity and producing successful outcomes

REFERENCES

1. Vertucci FJ. Root canal anatomy of the human permanent teeth. *Oral Surg Oral Med Oral Pathol.* 1984 Nov;58(5):589-99.
2. Barker BC, Parsons KC, Mills PR, Williams GL. Anatomy of root canals. III. Permanent mandibular molars. *Aust Dent J.* 1974 Dec;19(6):408-13.
3. AL-Rammahi, H.M., Chai, W.L., Nabhan, M.S. et al. Root and canal anatomy of mandibular first molars using micro-computed tomography: a systematic review. *BMC Oral Health* 23, 339 (2023).
4. Hatipoğlu FP, Mağat G, Hatipoğlu Ö, Al-Khatib H, Elatrash AS, Abidin IZ, Kulczyk T, Ahmed Mohamed Alkhawas MB, Buchanan GD, Kopbayeva M, Surendar S BDS, MDS, Javed MQ,

Madfa AA, Bürklein S, Mimica S, Bhatti UA, Maratovna TI, Palma PJ, Brochado Martins JF. Assessment of the Prevalence of Radix Entomolaris and Distolingual Canal in Mandibular First Molars in 15 Countries: A Multinational Cross-sectional Study with Meta-analysis. *J Endod.* 2023 Oct;49(10):1308-1318.

5. Garg AK, Tewari RK, Kumar A, Hashmi SH, Agrawal N, Mishra SK. Prevalence of three-rooted mandibular permanent first molars among the Indian Population. *J Endod.* 2010 Aug;36(8):1302-6.

6. Manik K, Ikhar A, Patel A, et al. (May 03, 2024) Morphometric Analysis of Radix Entomolaris: Implications for Endodontic Access and Treatment. *Cureus* 16(5): e59584.

7. Filip L. Calberson, DDS, MMS, Roeland J. De Moor, DDS, MMS, PhD, and Christophe A. Deroose, DDS, MMS

8. Van der Vyver, P.J. & Vorster, M. 2017, 'Radix Entomolaris : literature review and case report', *South African Dental Journal*, vol. 72, no. 3, pp. 113-117.

9. Sathyan M, James B, Devadathan A, et al. Radix Entomolaris with Middle Mesial Canal: A Rare Case. *Cons Dent Endod J* 2019;4(2):44-48.

The Management of Maxillary Midline Diastema - A Clinical Case Report

Abstract

Introduction: The Maxillary Midline diastema is the most common aesthetic problem in mixed and early Permanent dentitions. The gap may be caused by developmental, pathogenic, or by iatrogenic reasons. Young adults who have a gap between their central incisors more than 4 mm may experience aesthetic issue. There are various innovative therapies are available, extending from the frenectomy to the composite build up and the Orthodontics. This case study Demonstrates the treatment of a patient who has midline diastema and Angle's Class I Malocclusion. This case included the Frenectomy procedure for correction of the abnormal labial Frenal attachment followed by space closure. The aim of this procedure is to improve and ensure functional occlusion while enhancing the aesthetic issues.

Dr. Nabeel Aftab¹
Dr. Abhishek Singha Roy²
Dr. Santosh Kumar³
Dr. Ravi Ranjan⁴
Dr. Kaushal Mishra⁵
Dr. Alok Kumar⁶

Drnabeelaftab.in@gmail.com¹
Asr.orthodontist@gmail.com²
Santu625@gmail.com³
Rav2089@gmail.com⁴
kaushalmishraa121@gmail.com⁵
alok2708@gmail.com⁶

*Department Of Orthodontics and Dentofacial
Orthopaedics.^{1,2,3,4,5,6}
Post Graduate Trainee.^{1,4,5,6}
Prof. and H.O.D.²
Reader.³*

*Mithila Minority Dental College and Hospital,
Darbhanga, Bihar.^{1,2,3,4,5,6}*

Corresponding Author

Dr. Ravi Ranjan

*Mithila Minority Dental College & Hospital,
Darbhanga- 846001,
Bihar, India*

Email: *Rav2089@gmail.com*

INTRODUCTION

The term diastema, is derived from the Greek word meaning “interval” or “space,” refers to a space or gap between two or more adjacent teeth. Diastemata can occur in both the maxillary and mandibular arches, but they are most commonly observed in the anterior maxillary region between the two central incisors. When present in this specific location, the condition is referred to as a, or midline diastema. One of the most frequent aesthetic concern in orthodontic practice is maxillary anterior spacing. Patients and their parents often seek treatment for diastema closure due to its impact on facial appearance, smile esthetics, and self-confidence. Midline diastema may be physiological during the mixed dentition stage, especially during the eruption of maxillary lateral incisors and canines, but persistence beyond adolescence often indicates an underlying etiologic factor requiring clinical attention. Keene¹ defined midline diastema as anterior midline spacing exceeding more than 0.5 mm between the proximal surfaces of Adjacent teeth. Kaimenyi in his study reported that the incidences of maxillary and mandibular midline diastema are 14.8% and 1.6%.¹ Midline diastema was more common in the maxilla than in the mandible.²

Midline diastema is highly prevalent in early childhood, observed in nearly 98% of six-year-olds, but the incidence significantly decreases with age. By the age of 11, the prevalence drops to approximately 49%, and further declines to around 7% in individuals aged 12 to 18 years. In adult populations, the reported prevalence ranges from 1.6% to 25.4%, depending on the criteria used for measuring the midline diastema. Notably, higher prevalence rates are consistently documented among younger age groups.³

A midline diastema may arise from a variety of underlying causes, such as proclination of the maxillary anterior teeth, the presence of a prominent labial frenum, congenitally missing teeth, peg-shaped lateral incisors, or midline supernumerary teeth. In some cases, it may also result from self-inflicted trauma, such as that associated with tongue piercings⁴. Additionally, oral habits like tongue thrusting and digit sucking are recognized as significant contributing factors in the development and persistence of midline diastema.¹⁶⁻¹⁷ When the labial frenum inserts into the notch of the alveolar bone, a band of dense fibrous tissue may form between the central incisors, resulting in a maxillary midline diastema.⁵

In certain cases, the alveolar bone surrounding each central incisor may fail to extend fully to the midline suture, resulting in widely spaced central incisors. When this occurs, bone is not deposited beneath the labial frenum, leading to the formation of a V-shaped bony cleft between the teeth. This structural defect contributes to the development of an aberrant frenum attachment. Additionally, the midline diastema may persist indefinitely, as transseptal fibers are unable to traverse the cleft to unite the adjacent teeth.⁶ The extent and aetiology of the diastema must be thoroughly evaluated. Good dental hygiene, suitable treatment selection, acceptable patient cooperation, and proper case selection are all essential.⁷ In this case report, the main etiological factor is associated with high labial frenal attachment.

The objective of this article is to present a clinical case involving a 24-year-old female patient with a midline diastema associated with a high labial frenal attachment, which was successfully managed through fixed orthodontic appliance therapy in conjunction with a labial frenectomy, resulting in a favorable esthetic and functional outcome.

CLINICAL REPORT

A Female patient aged 20 yrs reported to the Department of Orthodontics and Dentofacial Orthopedics at Mithila Minority Dental College and Hospital, Darbhanga, having the chief complaint of spacing in the upper front teeth region. The patient reported that the spacing had been present for several years and had not shown any signs of spontaneous closure. Her medical history was non-contributory, with no reported systemic illnesses or medications.

Clinical Findings

An intraoral examination showed a noticeable midline diastema between the maxillary central incisors, around 7 mm in length. A high labial frenal attachment was observed, characterized by a thick, fibrous band extending from the inner aspect of the upper lip into the anterior maxillary alveolar mucosa. A prominent fibrous nodule was palpated in the region of the incisive papilla, suggesting an abnormal insertion of the frenum into the interdental and papillary area (Figure 5). The blanching test was executed by employing digital pressure on the frenum while analyzing the palatal mucosa. A distinct blanching effect was distinguished in the papillary region, confirming the pathological nature of the frenal attachment.

The patient exhibited a bilateral Angle's Class I molar relationship, indicating a favorable anteroposterior skeletal relationship with no evidence of posterior crossbite or crowding (Figures 3 & 4). Overjet and overbite were within normal limits.

Radiographic Evaluation

To rule out other potential etiologies for the diastema, including mesiodens, odontomas, or other anomalies, a panoramic radiograph (orthopantomogram) was obtained (Figure 8). The radiographic analysis showed normal dentition without the presence of supernumerary teeth, root anomalies, or pathological radiopacities in the anterior maxillary region. The central incisors demonstrated well-formed roots with no signs of dilaceration or periapical pathology.

Diagnosis

Based on clinical and radiographic findings, a diagnosis of a maxillary midline diastema secondary to a high labial frenal attachment was made. The blanching test served as a reliable adjunctive diagnostic tool to confirm the mechanical influence of the frenum on anterior tooth spacing.

TREATMENT PROGRESS-

To manage the 7 mm midline diastema, a treatment plan was formulated involving bodily movement of the maxillary central incisors using a fixed appliance in combination with a labial frenectomy. Preadjusted edgewise brackets (0.022 x 0.028-inch slot) were bonded to the maxillary arch, and 0.014-inch round nickel-titanium archwire was engaged to initiate alignment and leveling. Once alignment was achieved, anterior space closure was initiated using elastomeric chain (e-chain).

When the midline gap was reduced to less than 1 mm, a labial frenectomy was performed (Figures 9 & 10). Immediately following the surgical procedure, the remaining space was closed with an e-chain extending from canine to canine in the same visit. Within six months, large midline diastema had completely closed.. To maintain the achieved tooth positions and prevent relapse, the brackets were tied using a figure-of-eight ligation technique. An intraoral periapical radiograph taken at this stage confirmed parallel alignment of the

central incisor roots, indicating that the diastema was closed through true bodily movement rather than tipping.

Following space closure, a flexible, directly bonded lingual retainer was placed on the palatal surfaces of the anterior teeth. Subsequently, the fixed appliance was debonded, and comprehensive post-treatment records were obtained, including intraoral and extraoral photographs, periapical and panoramic radiographs (OPG), and study models. The final outcome was esthetically satisfactory, resulting in a positive psychological impact and increased confidence for the patient.

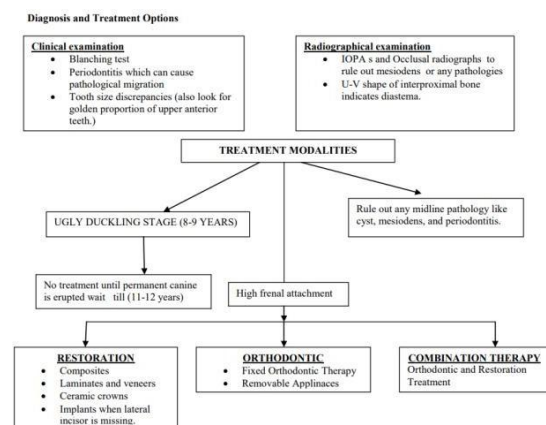


Fig-1: Diagnosis & treatment options

PRETREATMENT INTRA ORAL PHOTOGRAPHS

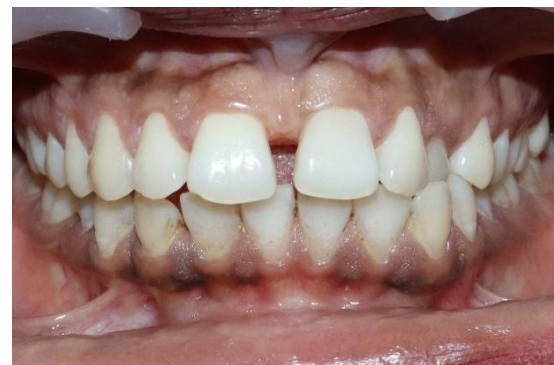

Fig-2: intraoral frontal view

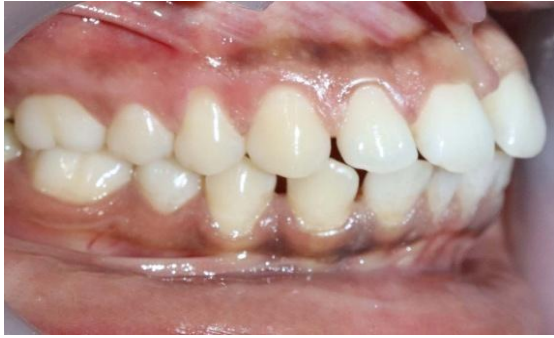

Fig-3: intraoral Right lateral view

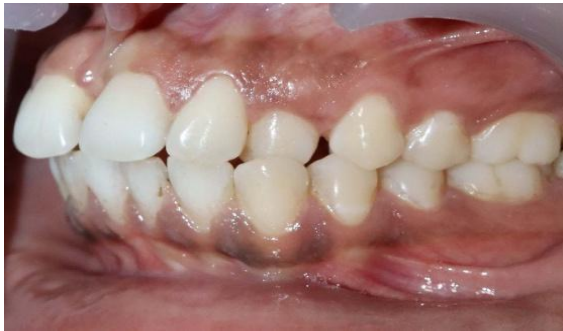

Fig-4: intraoral left lateral view

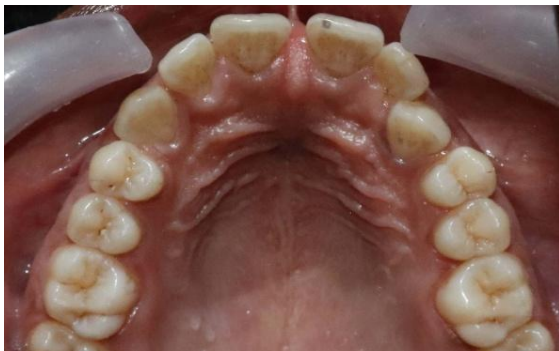

Fig-5: intraoral maxillary occlusal view

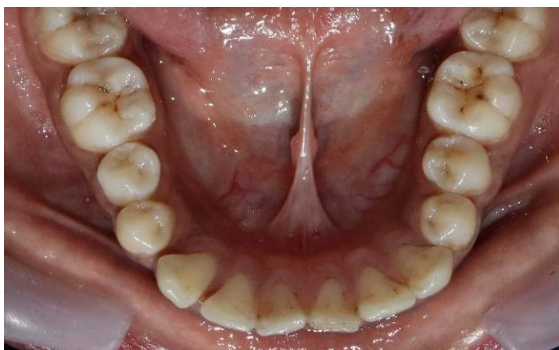

Fig-6: intraoral mandibular occlusal view

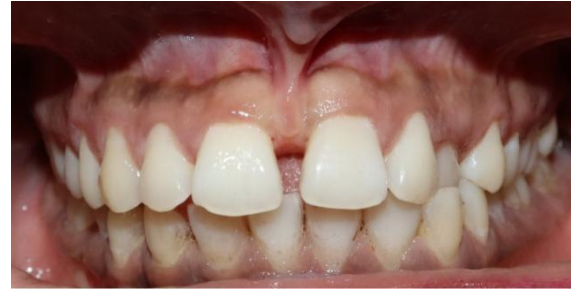

Fig-7: high frenal attachment papillary type with nodules

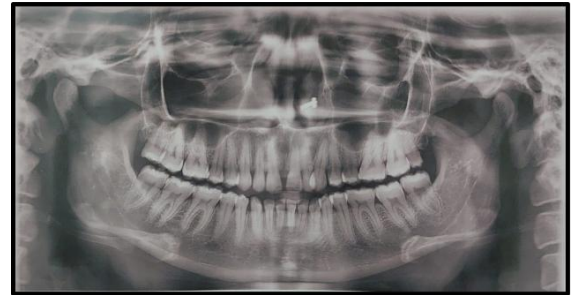


Fig-8: OPG

BEFORE FRENECTOMY

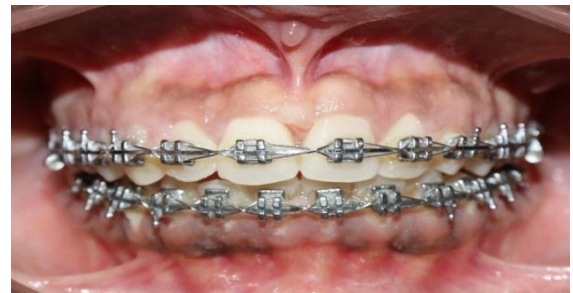

Fig-9: Before Frenectomy

POST-HEALING

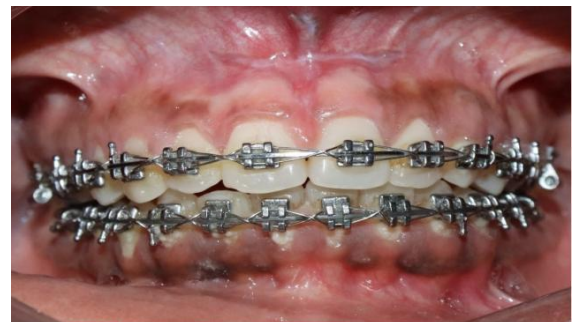

Fig-10: Post Healing

DISCUSSION

Midline diastema is often regarded as a self-correcting developmental anomaly, particularly around the age of 11 years⁸⁻¹⁰. In many cases, the space naturally resolves with the eruption of the permanent maxillary canines. However, studies have shown that in approximately 17% of cases, the diastema persists even after canine eruption.¹¹

The presence of spacing or midline diastema may be attributed to various etiological factors, including microdontia, supernumerary teeth, or—as observed in the current patient—a high or aberrant labial frenal attachment. While minor diastemas and spacing may sometimes be managed with composite restorations, the long-term prognosis of such restorative approaches remains questionable. Composite materials are prone to discoloration, fracture, and may result in over-contoured teeth, especially when used inappropriately in non-microdontia cases.

One of the major concerns associated with diastema closure is its high tendency for relapse. Therefore, the use of a permanent bonded lingual retainer is often recommended post-treatment to ensure long-term stability. This type of retainer is generally well accepted by patients due to its esthetic advantage and passive design.

The elimination of the underlying etiology is essential for the stable and long lasting outcome. In cases involving an abnormal labial frenum, frenectomy is indicated to reduce the risk of relapse¹². While performing the frenectomy before orthodontic tooth movement may offer better surgical access and visualization, some clinicians caution that scar tissue formation following early surgery may interfere with subsequent space closure¹³.

Relapse is still a major problem when it comes to treating midline diastema. Achieving a stable and lasting outcome relies heavily on the accurate identification and elimination of the underlying cause. In cases involving a large diastema, the use of long-term retention protocols, including permanently bonded lingual retainers, is strongly recommended to maintain the correction¹⁴. Additionally, those with a positive family history and those who present with a large pre-treatment diastema have a significantly higher chance of relapsing, which may indicate a genetic or hereditary component¹⁵.

REFERENCES

1. Keene HJ. Distribution of diastemas in the dentition of man. *Am J Phys Anthropol* 1963;21:437-41
2. Kaimenyi JT. Occurrence of midline diastema and frenum attachments amongst school children in Nairobi, Kenya. *Indian J Dent Res* 1998;9:67-71.
3. Foster TD, Grundy MC: Occlusal changes from primary to permanent dentitions . *Br J Orthod*. 1986, 13:187-93. 10.1179/bjo.13.4.187
4. Edwards JG: The diastema, the frenum, the frenectomy: a clinical study . *Am J Orthod*. 1977, 71:489-508. 10.1016/0002-9416(77)90001-x
5. Deepa G: Attachment of maxillary frenum and occurrence of midline diastema in children . *J Pharm Sci Res*. 2016, 6:536-9.
6. Hussain U, Ayub A, Farhan M: Etiology and treatment of midline diastema: a review of literature . *Pak Orthod J*. 2013, 5:27-33.
7. Mavreas D. Self-Ligation and the Periodontally Compromised Patient: A Different Perspective. *Seminars in Orthodontics*, Vol 14, No 1 (March), 2008: pp 36-45
8. Tanaka OM, Morino AY, Machuca OF, Schneider NA: When the midline diastema is not characteristic of the “ugly duckling” stage. *Case Rep Dent*. 2015, 2015:924743. 10.1155/2015/924743
9. Masłowska-Kasowicz A, Nowicka-Dudek K, Zadurska M, Shybinsky V, Lesitskiy M, Chukhray N: The incidence of malocclusions in children at the “ugly duckling” stage. *Orthod Forum*. 2019, 15:14-26. 10.5114/for.2019.86606
10. de Melo ML, de Azevedo MM, Floriano I, Tannure PN, Neves AB, Imperato JC: Impact of mesiodens management on the oral health-related quality of life of a child: a case report. *Rio J Dent J*. 2021, 31:53-60
11. Laverty DP, Thomas MB: The restorative management of microdontia . *Br Dent J*. 2016, 221:160-6. 10.1038/sj.bdj.2016.595
12. Bouts EA, Tatakis DN: Maxillary labial frenum attachment in children . *Int J Paediatr Dent*.

2011, 21:284-8. 10.1111/j.1365-263X.2011.01121.x

13. Sewerin I: Prevalence of variations and anomalies of the upper labial frenum . Acta Odontol Scand. 1971, 29:487-96. 10.3109/00016357109026535

14. Durbin DD. Relapse and the need for permanent fixed retention. J Clin Orthod 2001; 35(12): 723–727.

15. Shashua D, Artun J. Relapse after orthodontic correction of maxillary median diastema: a follow-up evaluation of consecutive cases. Angle Orthod 1999; 69: 257–263.

16. Gellin ME. Digital sucking and tongue thrusting in children. Dent Clin N Am 1978; 22(4): 603–619.

17. Curzon ME. Dental implications of thumb-sucking. Paediatrics 1974; 54(2): 196–200.

Utility Arch: Transforming Upper Incisor Alignment Effectively

Abstract

Introduction: Facial symmetry refers to a complete match in An essential and adaptable tool that supports both comprehensive and interceptive orthodontic treatments is the utility arch. It can be applied to permanent or mixed dentition at various phases of orthodontic treatment.

Originally developed in 1977 by C.J. Burstone, the utility arch was formed to align the arch utilizing biomechanical principles. Ricketts improved and modified the utility arch over time, and it now forms an essential component of Bioprogressive Therapy. The utility arch is particularly useful for intruding, protruding, retruding and holding the anterior teeth.

The purpose of this research is to present a number of case studies that explore a novel orthodontic treatment strategy for Angle's class I malocclusion that makes use of passive and protraction utility arches. Case studies provide clear illustrations of its design and use.

Keywords: Angle's class I malocclusion, Auxiliary, Bioprogressive Therapy, Protraction, Passive/Holding, Utility arch.

Dr. Ravi Ranjan¹
Dr. Abhishek Singha Roy²
Dr. Mehedi Hasan³
Dr. Shivangi Kumari⁴
Dr. Nabeel Aftab⁵
Dr. Kumari Anuradha⁶

rav2089@gmail.com¹
asr.orthodontist@gmail.com²
mehedihasan42@gmail.com³
shivangibokaro12@gmail.com⁴
drnabeelaftab.in@gmail.com⁵
anuradhasbbdc123@gmail.com⁶

*Department Of Orthodontics and Dentofacial
Orthopaedics.^{1,2,3,4,5,6}
Post Graduate Trainee.^{1,5,6}
Prof. and H.O.D.²
Reader.³
Senior lecturer.⁴*

*Mithila Minority Dental College and Hospital,
Darbhanga, Bihar.^{1,2,3,4,5,6}*

Corresponding Author

Dr. Nabeel Aftab⁵

*Mithila Minority Dental College & Hospital,
Darbhanga- 846001,
Bihar, India*

Email: *drnabeelaftab.in@gmail.com⁵*

INTRODUCTION

Children with a range of early occlusal abnormalities can benefit from preventive and interceptive orthodontic treatments in their primary and mixed dentitions, which also enable the proper development of skeletal patterns.¹ Early orthodontics aims to improve the orofacial environment by resolving dentoalveolar irregularities, functional interferences, and skeletal and muscular imbalances before the permanent teeth fully emerge, thereby simplifying or eliminating the need for later orthodontic treatment.²

The utility arch, one of the most versatile auxiliary arch wires, can be used in both permanent and mixed dentition at various stages of orthodontic treatment. In order to balance the occlusion, this fixed appliance is an orthodontic treatment method used specifically for permanently misaligned upper incisors.³ According to the biomechanical principles that Burstone explained, it was first created as a way to level the curve of spee in the jaw.^{4,5} It has since been changed to do many more things and is now an important portion of Bioprogressive Therapy.^{6,7} The utility arch only touches the first molars and incisors, while the full arch goes across both buccal segments.⁸

CONSTRUCTION

The utility arch is a continuous archwire that spans both buccal segments, however it is made of different wires for different purposes and depends on the arch it is utilised in. For a .018" appliance, the recommended wire for the mandibular arch is .016" x .016" or .016" x .022" Blue Elgiloy. For most maxillary arches, .016" x .022" Blue Elgiloy is suggested. With a .022" appliance, .019" x .019" Blue Elgiloy can be utilised in either arch.⁷ When employing utility arches in conjunction with complete arch appliances, it is required to place auxiliary tubes on the first molar bands. The main buccal tube or bracket on the first tooth can be used to posteriorly anchor the utility arch in cases where the buccal segments are not banded during the pre-orthopedic phase of treatment.⁸

Charles Burstone's invention of TMA wires in 1981 introduced features like as high spring back and good formability with low stiffness, resulting in significant deflections with modest forces. Utility arches are now constructed using TMA wires.

Case I:

A 9-year-old girl patient presented to the department with the primary complaint of protruding upper anterior teeth (Fig. 1). During the intraoral clinical examination, she presented with Angle's class I malocclusion. The overjet was markedly augmented, and a partially erupted canine was observed in the maxillary arch.

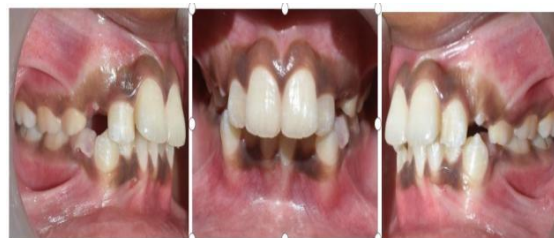

Fig-1: Pretreatment Intraoral Photographs

Consequently, it was determined to provide a holding utility arch to stabilise the upper dentition, anticipating the mandibular growth to align accordingly. An initial alignment phase was conducted utilising a .016 NiTi archwire (Fig. 2).

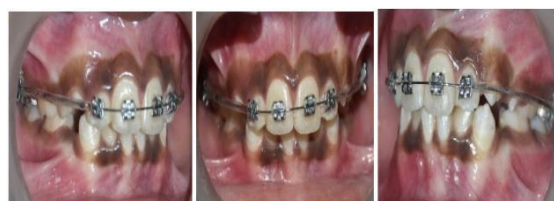

Fig-2: Using a 0.016 NiTi segmental archwire for levelling and alignment

The maxillary arch has a passive holding utility arch (Fig. 3). Irregularities in the alignment of the anterior teeth are often rectified using a sectional levelling arch prior to the placement of a utility arch. The passive utility arch serves to stabilise or maintain space in both mixed and permanent dentition. It is optimal during the mixed dentition phase, as it facilitates the eruption of the canines and premolars. It makes it easier to maintain arch length during the dentition transition. It is utilised in permanent dentition, primarily for the preservation of anchoring. A passive utility arch, by definition, remains inactive and should not reposition teeth in any direction.

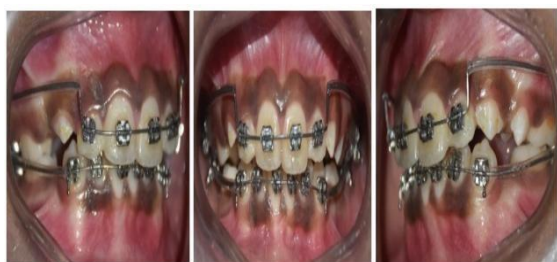

Fig-3: Passive upper utility arch

A passive utility arch originates from the auxiliary tube of the first molar. The molar section of the arch wire is trimmed to align with the distal edge of the auxiliary tube. A 90° bend is created immediately anterior to the tube using a 142 arch-forming plier, followed by the formation of a posterior vertical step, typically measuring 3-4mm in length. In order to ensure that the horizontal or vestibular part extends anteriorly in parallel to the occlusal plane, a further right-angle bend is integrated into the wire. Another right-angle bend directs the wire towards the occlusal surface at the lateral and canine incisor junction. Following a vertical anterior step of 5-8mm, a final 90-degree bend forms the incisal segment, which must align within the brackets of the lower anterior teeth. Irregularities in the alignment of the lower anterior teeth are often rectified using a sectional levelling arch prior to the application of a utility arch. The arch wire extends in a manner analogous to the contralateral molar.

Case II:

An 11-year-old male patient presented to the department with the primary complaint of abnormal upper front teeth. He had Angle's class I malocclusion, which included retroclination of both upper central incisors (Fig. 4).

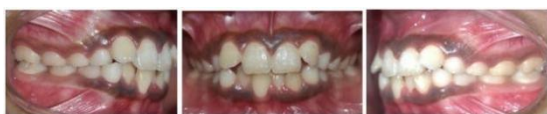

Fig-4: Pretreatment Intraoral Photographs

A protraction utility arch was chosen to procline both upper central incisors, ensuring they align with the rest of the upper arch dentition. The protraction Utility arch was initially activated 2 mm in front of the incisor bracket slots. (Fig. 5). The protraction was successfully completed in four months (Fig. 6). A preliminary segmental aligning

phase was conducted utilising a .016 NiTi archwire (Fig. 7).

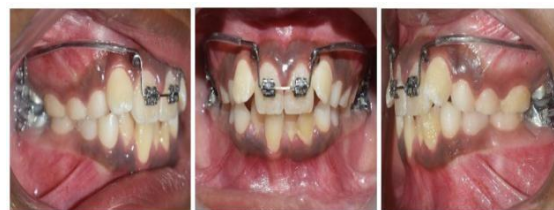

Fig-5: Upper Protraction utility arch placed

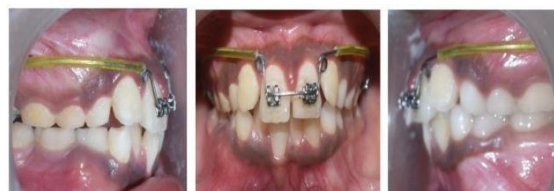

Fig-6: After 4 months of protraction

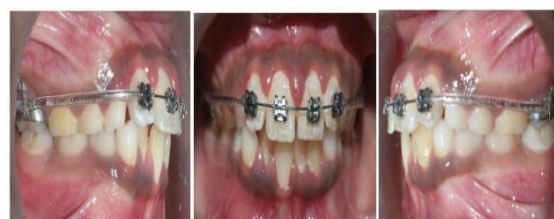

Fig-7: Leveling and aligning using .016 NiTi segmental archwire

The protrusion utility arch helps in the proclination of upper and lower incisors. This technique is primarily utilised for flaring and intruding maxillary incisors. The posterior vertical step of the protrusion arch should be aligned with the auxiliary tube. The vestibular segment runs forward to the interproximal area between the canine and lateral incisor. A loop is then positioned occlusal to the vestibular segment and distal to the anterior vertical step using a loop-bending plier. The anterior leg of the loop ought to be placed mesially, thereby offering a degree of canine offset. The anterior vertical step measures between 5 and 8 mm in length, varying according to the patient's tolerance. The utility arch is completed in a similar way on the other side when the incisal section passes through the incisor brackets.

The anterior section should be placed around 2 mm anterior to where it is normally expected in the incisor brackets when the protrusion utility arch is in a passive state. The protrusive force is generated by connecting the anterior segment of the utility

arch to the anterior brackets. For intrusion, a gable bend in the vestibular segment that is orientated occlusally can be used. The protrusion arch is engaged by detaching the anterior segment from the brackets, angling the posterior vertical step forward from 90 degrees to 45 degrees, and reinserting the archwire into the brackets. Additional modifications can be implemented in both the anterior and posterior vertical steps to enhance activation further.

DISCUSSION

It has been proposed that using removable appliances is a suitable way for treating narrow maxillary arches, teeth behind the bite, and anterior tooth malpositions.⁹ The drawbacks of removable appliances are their inability to manage tooth position and their limited ability to make single-point contact with teeth, which typically results in tipping movements.

Ninou and Stephens¹⁰ listed the main problems of removable expansion appliances as patient cooperation and retention of the appliance. The success of removable appliances obviously depends upon patient compliance, both for wearing and adjusting the appliance; the treatment will not work if this cooperation is not forthcoming. Removable appliances produce only buccal tipping of the molars during expansion, which may produce some buccal translation of the teeth during crossbite correction.

All the above listed problems can be overcome if an alternative to the removable appliances is found. As it enables control over the affected teeth during anterior crossbite correction or ectopic incisor alignment, the utility arch sectional fixed appliance provides more effective and efficient tooth positioning. This method can consequently be used to treat rotations, diastemas, and improper tooth inclinations and angulations relatively quickly.

An essential component of both comprehensive and interceptive orthodontic treatment is the utility arch. It is highly effective at protruding and retruding anterior teeth, and it is excellent for intruding both the upper and lower incisors. One of the major difficulties in correcting anteroposterior discrepancies is an impairment of anteroposterior tooth movement by anterior vertical interference. Upper and lower incisors can be moved gingivally using utility arches in orthopaedic and orthognathic surgical therapy to properly adjust tooth position. Despite advances in

fixed appliance systems and skeletal anchorage, the utility arch retains a vital role in orthodontic biomechanics. When employed judiciously, it provides an effective, efficient, and biologically sound means of achieving a variety of tooth movements- particularly in the vertical dimension. In today's orthodontist's armamentarium, accuracy in utility arch design and activation is still essential.

REFERENCES

1. Rohilla M, Bodh M, Kumar A, Namdev R. Early interception using 2×4 appliance: a case series. *International Journal of Advances in Case Reports*. 2017; 4: 226–229.
2. Suresh M, Ratnaditya A, Kattimani VS, Karpe S. One phase versus two phase treatment in mixed dentition: a critical review. *Journal of International Oral Health*. 2016; 7: 144–147.
3. DaSilva-Filho OG, Silva-Lara T, Bibiano GF, Fernández-Sánchez J. 4×2 leveling: importance of its application in mixed and permanent dentition. *Spanish Orthodontics*. 2006; 46: 167–178.
4. Burstone CD. Mechanics of the segmented arch technique. *Angle Orthod* 1966; 36:99-120.
5. Burstone CD. Deep overbite correction by intrusion. *Am J Orthod* 1977; 72:1-22.
6. Bench RW, Gugino CF, Hilgers JJ. Bioprogressive Therapy, Part VII: The utility and sectional arches in bioprogressive therapy mechanics. *J Clin Orthod* 1978; 12:192-207.
7. Ricketts RM, Bench RW, Gugino CF, Hilgers JJ, Schulhof RJ. *Bioprogressive Therapy*. Denver: Orthodontics, Rocky Mountain 1979.
8. McNamara JA. Utility arches. *J Clin Orthod*. 1986 Jul;20(7):452-6.
9. O'Brien K. Guest Editorial: Undergraduate orthodontic education: what should we teach rather than what can we teach? *Br J Orthod* 1997; 24: 333–334.
10. Ninou S, Stephens C. The early treatment of posterior crossbites: A review of continuing controversies. *Dent Update* 1994; 21: 420–426.

Prosthetic management of missing teeth – A Case Report

Abstract

Introduction: Loss of tooth in children is associated with various etiological factor and may lead to several potential sequelae as a result of tooth loss. The key for successful rehabilitation of young patients with missing teeth is to start it at a very early stage. There are various option to replace a missing tooth and one of them is removable partial Denture (RPD).

Case Report: In this case report a young female lost her teeth 2years back because of trauma which lead to avulsion of the tooth and so the missing tooth were successfully replaced by removable partial denture which was satisfactory to the patient.

Discussion: The removable partial denture is a very good alternative for replacement of missing teeth in young people which also help in building their confidence. This is highly acceptable to the people due to its convience of placement and removable and also is very cost effective compared to other methods of replacement of missing tooth

Conclusion: Prosthetic rehabilitation with a removable partial denture is a very good alternative for the replacement of missing tooth at a very early stage. It also help in gaing confidence for the individual.

Keywords: Protheses, Removable partial denture, Facial appearance, Missing, Dentition

Dr. Taskin Khan¹
Dr. Eeraveni Ranadheer²
Dr. Sunaina Bharti³
Dr. Richa Bharti⁴
Dr. Simmi Priya⁵

nehatakin16@gmail.com¹

*Department of Pediatric and Preventive
Dentistry.^{1,2,3,4,5}
Post Graduate Trainee.^{1,3,4}
Prof. and H.O.D.²
Reader.⁵
Senior lecturer.⁵*

*Mithila Minority Dental College and Hospital,
Darbhanga, Bihar.^{1,2,3,4,5}*

Corresponding Author

Dr. Taskin Khan

*Mithila Minority Dental College & Hospital,
Darbhanga- 846001,
Bihar, India*

Email: *nehatakin16@gmail.com*

INTRODUCTION

Multiple aetiologies affect missing teeth, including genetics and premature tooth loss. It is among the commonest complaints encountered in routine paediatric dental practice. In children, the absence of teeth may be caused by a multitude of etiological factors, including dental caries, trauma; genetic disorders such as cleft lip and palate, amelogenesis and dentinogenesis imperfecta, ectodermal dysplasia, as well as syndromes associated with orofacial abnormalities and cleft formation, such as Pierre-Robin and Van der Woude syndrome; cysts and tumours of the jaw; and periodontal diseases.

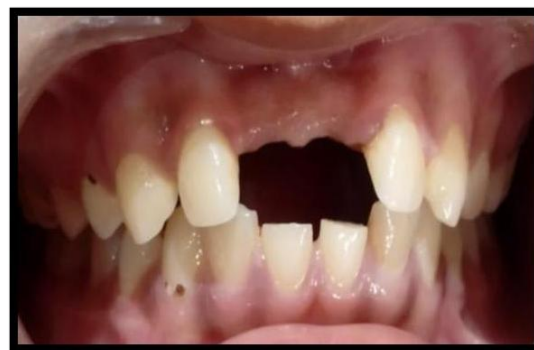Congenitally missing deciduous teeth have a global prevalence of 0.1–2.4%. Moreover, Permanent dental agenesis typically follows primary dental aplasia, with a prevalence of 0.15–16.2%.¹ The prevalence of premature primary tooth loss reported in several studies ranges from 4.3 to 42.6%

Teeth loss may affect facial appearance, mastication, and speech, which, as a result, has a huge impact on general and oral health and eventually on the quality of life. Hence, replacing the missing teeth with suitably constructed prostheses is highly demanded.

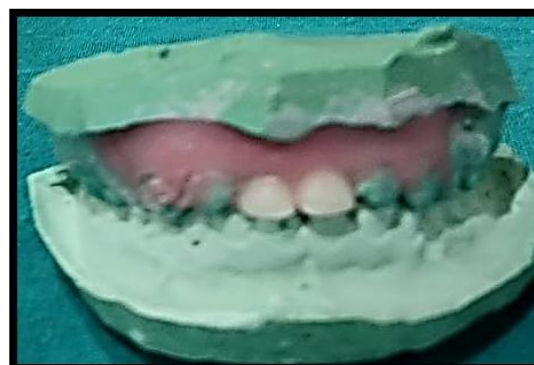Partially edentulous patients have various treatment options to replace missing teeth including implant-supported prostheses, or conventional fixed (FPD) or removable partial dentures (RPDs). RPDs are a common choice that is usually prescribed over FPDs or implant-supported prostheses for partially edentulous patients, especially when a relatively low cost and noninvasively alternative is indicated.

CASE REPORT

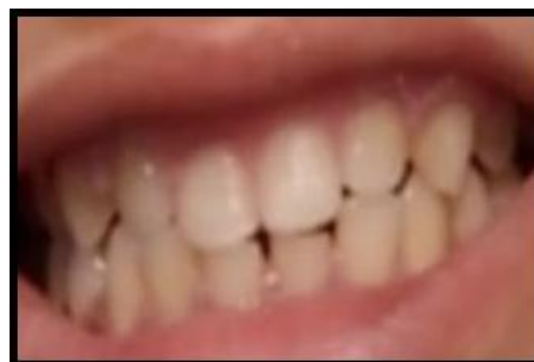A 12-year-old Female patient accompanied by her parent presented to the department of pediatric and prevent dentistry of Mithila Minority Dental College and Hospital with the chief complain of missing tooth in upper front teeth region since 2 years. No relevant medical or dental history was recorded. On oral examination, missing teeth were present w.r.t 11 and 21. Resultantly, removable partial dentures followed by regular follow ups were planned to ensure the retention of speech and aesthetics.



PRE – OP



RPD FABRICATION



POST - OP

DISCUSSION

Prosthetic therapy plays a key role in the provision and maintenance of functional and psychological integrity in pediatric patients with missing teeth, the loss of which may be attributed to various causes.

Caries- or trauma-associated tooth loss is among the most common causes necessitating pediatric prosthetic rehabilitation. Prevalence rates of 13.5

and 16.5%, respectively, have been reported in India by Reddy et al. and Ahamed et al. for premature deciduous tooth loss.

Another common reason for the need for prosthetic treatment in children includes the hereditary/genetic absence of teeth. Shetty et al. and Kathariya et al. prevalence rates of 0.32% and 4.8% for hypodontia in Karnataka and Maharashtra, respectively.

Both acquired or hereditary/genetic tooth loss necessitate prosthetic rehabilitation. Potential therapies include rehabilitation with a removable partial, fixed, or overlay dentures, or implants. However, continual jaw growth as well as other physical changes affect treatment planning in children.

CONCLUSION

A removable partial denture is good treatment of choice for anterior region, when patient is not ready for other treatment. It not only restores esthetics of patient but also function and self-confidence. For fabrication of such type of prosthesis, trained clinician and good lab support is mandatory.

REFERENCES

1. Rakhshan V. Congenitally missing teeth (hypodontia): a review of the literature concerning the etiology, prevalence, risk factors, patterns and treatment. *Dent Res J (Isfahan)* 2015;12(1):1–13.
2. Abdel-Rahman HK, Tahir CD, Saleh MM, et al. Incidence of Partial edentulism and its relation with age and gender. *Zanco J Med Sci* 2013;17:463–470
3. Sarangi D, Das S, Mohapatra A. Recall scheduling in removable prostheses patients. *Indian J Public Health Res Dev* 2018;9:1149.
4. Bhargava A, Sharma A, Popli S, et al. Prosthodontic management of a child with ectodermal dysplasia: a case report. *J Indian Pro*
5. McCracken WL. Partial denture construction. Principles and techniques . St. Louis: Mosby; 1960
6. Kavita K, Iqbal MA, Singh R, Singh S, Nazeer J, Singh R. Factors affecting patient satisfaction among patients undergone removable prosthodontic rehabilitation. *J Family Med Prim Care*. 2020;9(7):3544-8.

Operculectomy: A Case Report

Abstract

Introduction: Pericoronitis is defined as the inflammation of the gingival tissue surrounding the crown of a partially erupted tooth, most commonly affecting the mandibular third molar region. It can occur in acute, chronic, or subacute forms. The space between the partially erupted tooth and the overlying tissue flap offers an ideal site for debris retention and microbial proliferation. Management of pericoronitis often raises the question of whether to extract the tooth or perform an operculectomy. This report presents a case involving a 9-year-old patient with pericoronitis, successfully treated through conventional surgical operculectomy. In such cases, operculectomy is often favored over extraction due to its conservative nature and the potential to preserve the

Keywords: Pericoronitis, Mandibular third molar, Mandibular first molar, Operculectomy

Dr. Smriti Priya¹
Dr. Eeraveni ranadheer²
Dr. Anil Kohli³
Dr. Shafaque Muskan⁴
Dr. Kumari Rani⁵

priyasmriti3030@gmail.com¹
drranadheer@gmail.com²
anilkohli@ama@gmail.com³

Department of Pediatric and Preventive Dentistry.^{1,2,3,4,5}

Post Graduate Trainee.^{1,4,5}

H.O.D.²

Professor³

Mithila Minority Dental College and Hospital, Darbhanga, Bihar.^{1,2,3,4,5}

Corresponding Author

Dr. Smriti Priya

*Mithila Minority Dental College & Hospital,
Darbhanga- 846001,
Bihar, India*

Email: *priyasmriti3030@gmail.com*

INTRODUCTION

Pericoronitis is frequently encountered by Dental surgeons, commonly affecting partially erupted mandibular third molars due to limited space between the tooth and overlying gingival tissue. Management of these cases is often debated—whether to extract the third molar or facilitate its eruption. Extraction can be complex due to proximity to vital structures and associated risks such as pain, swelling, and trismus.

In contrast, operculectomy offers a minimally invasive alternative by removing the gingival flap covering the tooth, reducing inflammation risk and allowing a clearer eruption pathway without involving deeper anatomical structures.¹

Eruption disturbances, as classified by Kurol and Andreasen, include:

- Impaction:- eruption blocked by physical obstruction
- Primary retention:- eruption ceases before tooth emerges
- Secondary retention:- eruption discontinues after gingival penetration, with no obstruction

Contributing factors may include supernumerary teeth, abnormal eruption paths, cyst, or genetic predisposition. Second molars typically erupt around 12 years of age, and intervention between 10–14 years is ideal due to incomplete root formation and immature third molar development.

Treatment options include periodic monitoring, surgical exposure (operculectomy), or extraction—based on eruption progress and clinical findings.

CASE PRESENTATION

A 9-year-old male reported to the department of Pediatric and Preventive Dentistry, Mithila Minority Dental College and Hospital with a complaint of gingival flap covering the occlusal surface of the partially erupted mandibular first molar on left side since one month. Patient had discomfort in chewing food because of interruption by the gingival tissue. On clinical examination the operculum was covering the lower left first molar. After formulating the treatment plan and following oral prophylaxis, a local anesthesia was administered using 2% lignocaine with 1:80000 adrenalin to anesthetize the area. A triangular incision was made posterior to the distal surface of molar using No. 15 Bard – parker blade and a wedge shaped tissue was excised from the area.

The remaining tissue was curetted and the area was irrigated with Povidine –iodine solution. Postoperative instruction was given to the patient and their parents along with antibiotics and analgesics. The patient actively adhered to oral hygiene measures and made consistent efforts to keep the site clean. The patient had an uneventful healing.



Fig-1: Extra Oral View

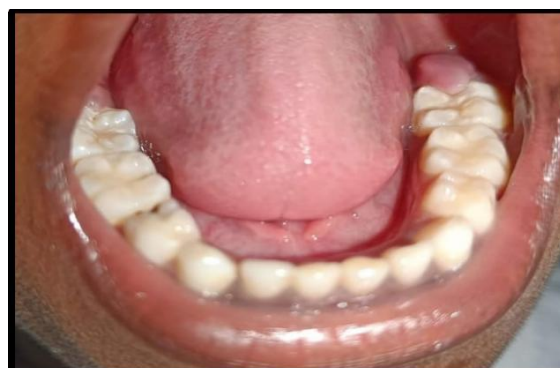

Fig-2: Intra Oral View

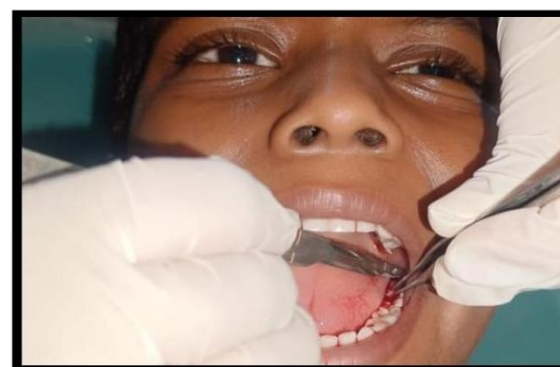


Fig-3: Intra Oral Photograph During The Procedure

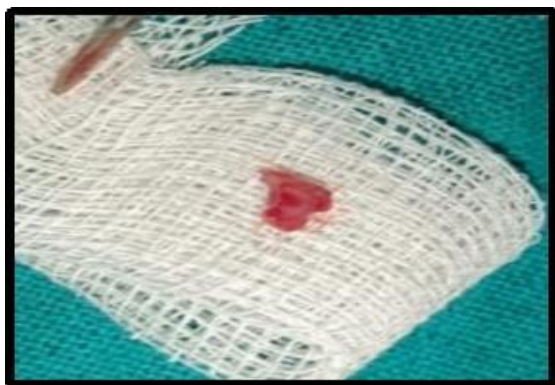

Fig-4: Excised Tissue

DISCUSSION

The operculum is a dense fibrous flap of tissue that commonly extends over roughly half of the occlusal surface of a partially or fully erupted molar. Pericoronitis typically presents with symptoms such as pain, swelling, and difficulty in opening the mouth. Even in the absence of noticeable symptoms, the inner surface of the operculum may exhibit chronic inflammation, ulceration, or infection. Acute episodes may be triggered by trauma, occlusal contact, or the accumulation of food debris beneath the tissue flap. If left untreated, pericoronal infections may progress to form abscesses, potentially spreading to oropharyngeal spaces or the base of the tongue, leading to difficulty swallowing.⁽³⁾

Severe infections can also involve regional lymph nodes such as the submandibular, cervical, and retropharyngeal groups, with rare but serious complications like peritonsillar abscess, cellulitis, or Ludwig's angina.^(4,5)

Standard treatment often involves antibiotics and sometimes extraction. However, operculectomy—the surgical removal of the operculum—offers a less invasive option for symptom relief and recurrence prevention, especially when extraction is not preferred. Due to the mobility of the tissue, removal using conventional instruments is difficult. Electrosurgery or radiosurgery offers improved precision and control.⁽²⁾

According to studies by Pepper, Renton, and guidelines from NHS and NICE, asymptomatic third molars without pathology should not be routinely extracted.⁽⁶⁻⁸⁾

CONCLUSION

Operculectomy is a minimally invasive and effective alternative to extraction in managing pericoronitis. It significantly reduces symptoms and recurrence risk with minimal complications and better patient compliance. In appropriate cases, it should be considered over extraction, especially when the third molar is asymptomatic or not disease-associated.

REFERENCES

1. Balamurugan R and Naveen Benson. Comparison of Two Treatment Modalities: Operculectomy vs. Third Molar Removal for Management of Pericoronitis. *J Dent Res Prac* 2019; 1(1): 7-10.
2. Neumann M g, Takei H H, Klokkevold P R, Carranza FA.1 Carranza' s Clinical th Periodontology 10 ed. WB Saunders Co.:2006. P 400-1
3. Jacobs MH. Pericoronal and Vincent's infections: bacteriology and treatment, *J AM DENT assoc* 30:392,1953.
3. Perkins AE: Acute infections around erupting mandibular third molars, *Br Dent J* 76:199,1944.
5. M Balaji. Textbook of Oral and maxillofacial rd surgery. 3 ed. Elseiver 2010. P 383.
6. Pepper T, Thomas K, Paul G. Treatment of mandibular third molars and pericoronitis in british military personnel: influence of guidelines from the national institute for health and clinical excellence. *British Journal of Oral and Maxillofacial Surgery*. 2016;54(10):1111-1115.
7. Renton T, Wilson NH. Problems with erupting wisdom teeth: signs, symptoms, and management. *British Journal of General Practice*. 2016;66(649):606-608.
8. Sripathi Rao BH, Gunachandra RB, Sandarbh SS. Comparison of healing process of operculectomy with laser and surgical knife. *International Journal of Current Research*. 2016; 8(1):25368-25373.

Frenectomy - A Case Report

Abstract

Introduction: The frenum is a fold of mucous membrane that links the lips and cheeks to the alveolar mucosa, gingiva, and underlying periosteum. When it is abnormally positioned too close to the gingival margin, it can compromise oral hygiene by making plaque control difficult and exerting undue muscular tension on the gingival tissues. A frenectomy is a commonly performed surgical procedure used to correct such abnormal frenum attachments. In the preset case, a 37-year-old male patient was referred from the Department of Orthodontics to the Department of Periodontics for management of a papillary-type labial frenum attachment gingival tissue surrounding the maxillary central incisors. To correct these issues, a frenectomy was carried out under local anaesthesia using a scalpel. This method has proven effective in enhancing the results of orthodontic treatment in cases involving high frenum attachments. After ensuring bleeding control, a periodontal pack was applied to support soft tissue healing and maintain the surgical site.

Dr. Rohit Bharadwaj¹
Dr. Ria Jha²
Dr. Kausar Parwez Khan³
Dr. Uzwal Kumar Jha⁴
Dr. Akshta⁵

riajhaofficial@gmail.com¹

*Department of Periodontology And
Implantology.^{1,2,3,4,5}*

*Mithila Minority Dental College and Hospital,
Darbhanga, Bihar.^{1,2,3,4,5}*

Corresponding Author

Dr. Ria Jha

*Mithila Minority Dental College & Hospital,
Darbhanga- 846001,
Bihar, India*

Email: *riajhaofficial@gmail.com*

INTRODUCTION

Achieving the perfect smile has long been driven primarily by aesthetic concerns, a trend that continues in the modern world. In adults, a midline diastema the persistent gap between the two upper central incisors is often perceived as a cosmetic flaw. One of the main contributing factors to this condition is an unusually large or improperly positioned frenum. Therefore, careful assessment of the frenum is important.^[1] When the frenum is located close to the gum line, it can negatively affect gum health by creating tension that may lead to gingival recession. As a result, reducing or modifying the frenum is important not only for improving appearance but also for maintaining healthy gums and preventing related complications.^[2]

A key component of this examination is the labial frenum a band of fibrous-mucous tissue that connects the lip to the alveolar mucosa or gingiva, and to the underlying periosteum. Frenal attachments are classified based on how far the muscle fibers extend: mucosal attachments end at the mucogingival junction, gingival attachments blend into the attached gingiva, and papillary attachments reach into the interdental papilla. In some cases, the frenum fibers may even extend over the alveolar ridge and affect the palatine papilla.^[3]

There are several reasons why frenum removal may be necessary. Firstly, an abnormal frenum attachment can lead to the development of a gap between the upper front teeth, known as a midline diastema. Additionally, when the frenum is tightly attached near the gum line, it can pull the gingiva downward, leading to gum recession and negatively impacting both function and the appearance of the smile. Furthermore, a low frenum attachment and shallow vestibule can cause various oral health and functional issues that often require a frenectomy.^[3]

Early diagnosis of these conditions is essential for effective management. When addressed promptly, it not only prevents complications but also supports better oral hygiene and overall oral health.^[3]

The presence of an attached labial frenum can make it difficult or even impossible to properly align the maxillary central incisors. Orthodontists differ in their opinions on when and whether a labial frenectomy should be performed. Some recommend early removal of the frenum to facilitate closure of the midline diastema and prevent interference. Others prefer to wait until after the gap has been closed, believing that the resulting scar tissue will help maintain the closure.

A less common approach involves leaving the frenum intact and instead placing bonded retainers on the central incisors to prevent the space from reopening.^[4]

The most appropriate treatment depends on the individual case. The appearance and contour of the gingival tissues play a critical role in the overall esthetics of both natural and prosthetic teeth. In patients undergoing orthodontic treatment with fixed appliances, gingival overgrowth is a common occurrence.^[5] This condition can increase plaque retention and lead to gingival inflammation. Additionally, orthodontic bands may cause discomfort and contribute to irritation of the gums.^[6]

CASE PRESENTATION

A 37 year-old male patient presented to the Department of Periodontics following a referral from the Department of Orthodontics due to an abnormal frenal attachment as shown in Figure 1. His past medical history was unremarkable. A comprehensive medical history review and periodontal examination were conducted, revealing a papillary-type frenal attachment upon clinical inspection. Hematological tests were performed and returned results within normal limits. As no contraindications were identified, a treatment plan including frenectomy was proposed. The patient provided written informed consent, and the surgical procedures were subsequently initiated.

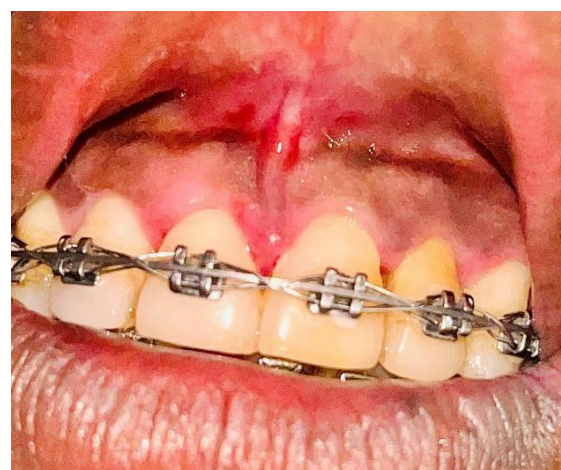

Fig-1: Pre-surgical photograph showing elevated frenum insertion.

Under strict aseptic conditions and local anesthesia, the conventional scalpel technique was employed to remove the abnormal labial frenum, which

extended to the periosteum. A hemostat was placed at the deepest point of the frenum to stabilize the tissue as shown in Figure 2.

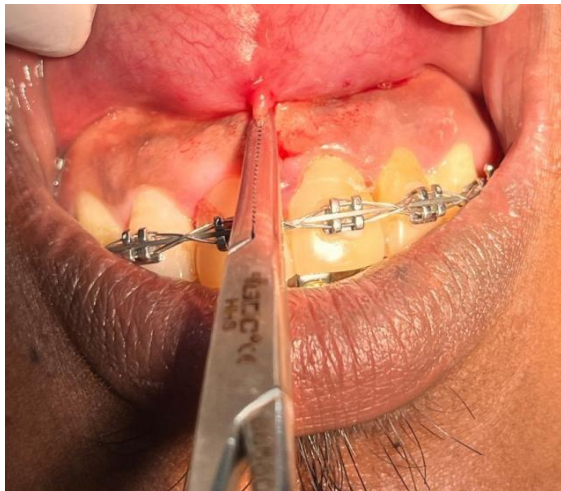

Fig-2: At the frenum's deepest region, a haemostat was used to secure the tissue.

Two incisions were then made along the upper and lower surfaces of the frenum, and a triangular, wedge-shaped section of tissue was excised, as shown in Figure 3. After excising the frenal fibers, additional undermining was performed using a scalpel. The resulting surgical site took on a diamond shape, and hemostasis was successfully achieved.

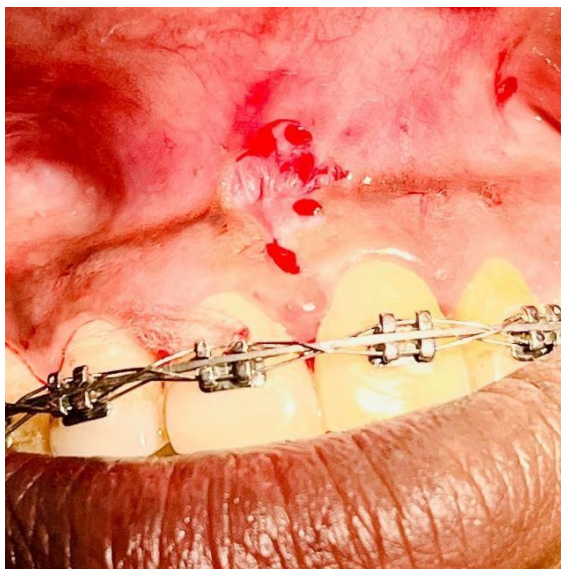


Fig-3: Labial frenectomy was executed using a traditional scalpel approach

The sutures were given at the surgical site to allow the tissues to blend as shown in Figure 4.

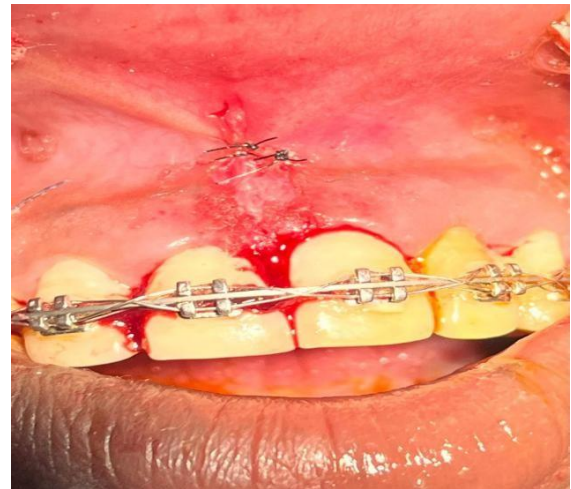


Fig-4: Suturing was performed at the site of surgery.

After achieving hemostasis, the periodontal pack was applied at the surgical site as shown in Figure 5. The sutures were removed after one week showing satisfactory healing and no signs of any infection or discomfort.

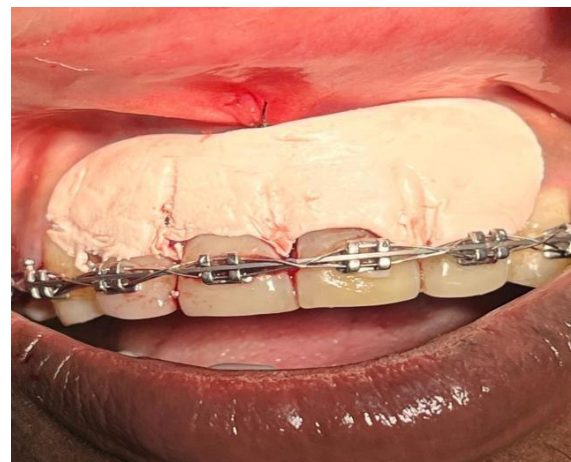


Fig-5: A protective periodontal pack was placed over the surgical site.

DISCUSSION

Dentistry has become a vital field in modern healthcare, playing a significant role in enhancing facial aesthetics. One structure of particular importance is the frenum, as it is a common contributing factor to the persistence of a midline

diastema the gap between the upper central incisors. In some cases, frenum surgery can be combined with procedures like gingivoplasty or gingival grafting to improve both functional and aesthetic outcomes.^[7]

When the frenum is attached too closely to the gum line, it can cause gingival recession. It is common for the maxillary frenum to insert into the anterior alveolar ridge, which is associated with various periodontal complications, including increased plaque accumulation, gingival recession, diastema formation, and other oral health issues. If left unaddressed, these problems may lead to gum disease, aesthetic concerns, and even tooth loss.^[8]

For patients presenting with a midline diastema caused by an abnormally positioned frenum, surgical intervention is often recommended. The goal is to remove the muscle fibers connecting the palatine papilla to the orbicularis oris muscle. Procedures such as frenectomy or frenotomy are designed specifically to manage these abnormal attachments and help restore both periodontal health and dental aesthetics.^[9]

Some practitioners have suggested that lasers and electrosurgery may serve as alternatives to traditional scalpel-based frenectomy procedures. These advanced techniques offer greater precision, allowing for controlled tissue manipulation and often promoting faster healing. However, they also present certain drawbacks for instance, they may result in long-term incisions that could lead to gum disease and aesthetic concerns. Scar formation is another important consideration, particularly when it interferes with orthodontic closure of a midline diastema. Therefore, in such cases, it is generally advised to delay frenum removal until after orthodontic treatment is completed.^[10]

Managing an abnormally positioned frenum and gingival overgrowth in orthodontic patients requires a comprehensive, multidisciplinary approach, considering both aesthetic outcomes and periodontal health. Frenal abnormalities can contribute to midline diastema and gingival recession, thereby compromising both the appearance of the smile and the integrity of the periodontal tissues.^[11]

The conventional frenectomy technique has some drawbacks, particularly for patients who experience anxiety or fear related to dental procedures. Potential issues include discomfort, minor scar formation, post-operative pain, and, in some cases,

delayed wound healing. However, suturing the site typically allows the wound to heal by primary intention, minimizing complications.^[12]

Devishree et al. reported that treating an abnormal frenum using modified surgical techniques can lead to both functional and aesthetic improvements, provided the appropriate method is selected. Bajaj et al. found that despite the complexity of the procedure, the Z-plasty technique delivered favourable aesthetic outcomes during orthodontic treatment. Similarly, Shirbhate et al. observed that V-Y plasty is a dependable option for managing defects resulting from frenectomy, offering effective tissue elongation and improved clinical results.^[13]

CONCLUSION

Orthodontic treatments, when combined with periodontal surgical procedures, can yield optimal outcomes in managing orthodontic patients. A thorough clinical evaluation is essential to determine the appropriate surgical approach. In the case presented, a combined procedure involving frenectomy was performed using the conventional scalpel technique, leading to significant improvements in both function and appearance. This integrated approach allows clinicians to enhance not only the esthetic appeal of the patient's smile but also their periodontal health, ultimately contributing to overall patient satisfaction and well-being.

REFERENCES

1. Huang WJ, Creath CJ: The midline diastema: A review of its etiology and treatment. *Pediatr Dent.* 1995, 17:171-9.
2. Sinha J, Kumar V, Tripathi AK, Saimbi CS: Untangle lip through Z-plasty. *BMJ Case Rep.* 2014, 2014:bcr2014206258.
3. Devishree, Gujjari SK, Shubhashini PV: Frenectomy: A review with the reports of surgical techniques . *J Clin Diagn Res.* 2012, 6:1587-92.
4. Prabhu M, Ramesh A, Thomas B: Treatment of orthodontically induced gingival hyperplasia by diode laser case report. *J Health Allied Sci NU.* 2015, 5:66-8.

5. Carranza F, Bascones A, Sanz M: Periodontology clinical de Glickman. Editorial Interamericana, Mexico; 1986,
6. Miresmaeili A, Farhadian N, Ejlali M: Interdisciplinary orthodontics: A case report. *Int J Orthod Milwaukee*. 2014, 25:37-40.
7. Hungund S, Dodani K, Kambalyal P, Kambalyal P: Comparative results of frenectomy by three surgical techniques conventional, unilateral displaced pedicle flap and bilateral displaced pedicle flap. *Dentistry*. 2013, 4:1-6.
8. Rathod S, Bawankar PV, Chikhale P, Bidwaikar A: Evaluation of variations in morphology and attachment of frenum in diverse population - A cross-sectional study. *Clin Epidemiol Glob Health*. 2020, 8:1094-7.
9. Fiorotti RC, Bertolini MM, Nicola JH, Nicola EM: Early lingual frenectomy assisted by CO2 laser helps prevention and treatment of functional alterations caused by ankyloglossia. *Int J Orofacial Myology*. 2004, 30:64-71.
10. Ghosh S, Nair V, Arora R: Frenectomy using scalpel in the classical technique- a case report . *J Case Rep Med Sci*. 2021, 7:8-12.
11. Shirbhate U, Bajaj P, Oza R, Solanki D: Management using V-Y plasty approach for abnormal frenal attachment: A case report. *Cureus*. 2024, 16:e57663.
12. Bajaj P, Shirbhate U, Subhadaresanee C, Thakre S: Management of aberrant frenum by Z-plasty procedure: A case report. *Cureus*. 2024, 16:e51853.
13. Shirbhate U, Bajaj P, Solanki D, Dare S, Sarangi S: Management of orthodontic-induced gingival enlargement: A case report. *Cureus*. 2023, 15:e47660.

Gingival Depigmentation Using Scalpel Technique: A Case Report

Abstract

Introduction: Dark pigmentation of the gums is a frequent aesthetic issue that concerns many people. While it does not indicate any underlying health problem, dark gums are often viewed as cosmetically unappealing. This condition, referred to as gingival hyperpigmentation, is generally inherited and is more precisely termed physiological or racial pigmentation. Its occurrence and severity differ among various ethnic groups.

For those who wish to enhance the appearance of their gums, multiple cosmetic treatment methods are available to reduce or eliminate the pigmentation. These include procedures such as chemical cauterization, bur abrasion, scalpel excision, cryosurgery, electrosurgery, gingival grafts, and laser treatment.

Dr. Mithilesh Bhagat¹
Dr. Raghav Narayan Jha²
Dr. Kausar Parwez Khan³
Dr. Amjad Tasheen⁴
Dr. Iswar Chandra Vidyasagar⁵

sarvsamadhanclinic@gmail.com¹

*Department of Periodontology And
Implantology.^{1,2,3,4,5}*

*Mithila Minority Dental College and Hospital,
Darbhanga, Bihar.^{1,2,3,4,5}*

Corresponding Author

Dr. Raghav Narayan Jha

*Mithila Minority Dental College & Hospital,
Darbhanga- 846001,
Bihar, India*

Email: *aanviraj.17@gmail.com*

INTRODUCTION

Physiological pigmentation of the oral mucosa typically appears as multifocal or widespread melanin deposits, with the degree of pigmentation varying among different ethnic populations. Melanin, a naturally occurring brown pigment, is the primary factor responsible for endogenous gingival discoloration. This condition becomes more noticeable in individuals with a "gummy smile" or excessive gingival exposure during smiling.

Gingival depigmentation is a form of periodontal plastic surgery aimed at reducing or eliminating gingival hyperpigmentation through various treatment methods. This case report presents a straight forward and efficient surgical approach for gingival depigmentation that does not rely on advanced equipment, yet achieves aesthetically pleasing outcomes and high patient satisfaction.

CASE REPORT

A 20-year-old female patient presented to the Department of Periodontology and Oral Implantology unit at Mithila Minority Dental College and Hospital, Darbhanga with a primary concern regarding the blackish discoloration of her upper and lower anterior gingiva (Figure 1), which she found aesthetically displeasing. The pigmentation was not accompanied by any symptoms such as numbness, ulcers, or discharge. She was systemically healthy and had no history of smoking.

Clinical examination revealed pronounced melanin pigmentation extending from the right first premolar to the left first premolar in both the maxillary and mandibular arches. At the patient's request for an aesthetic solution to improve the appearance of her "black" gums, a surgical depigmentation procedure using a scalpel was planned.

Following administration of local anesthesia, a Bard-Parker handle with a No. 15 blade was used to carefully excise the pigmented epithelium (Figure 2). Hemorrhage was managed by applying pressure with sterile gauze. The pigmented epithelial layer along with a thin portion of the underlying connective tissue was removed. The treated area was then irrigated with normal saline, and a periodontal dressing was placed to protect the site.

Postoperative care included prescriptions for antibiotics (Amoxicillin 500 mg, three times daily for 5 days) and anti-inflammatory analgesics (a

combination of Ibuprofen and Paracetamol, three times daily for 3 days). The patient was also instructed to rinse with 0.2% chlorhexidine gluconate mouthwash twice daily for one week to support healing and maintain oral hygiene.

The patient was followed up after 1 week, and subsequently at 1, 3, and 9 months. Healing progressed smoothly, with no reports of postoperative pain or sensitivity. The gingival tissue appeared healthy, and no signs of repigmentation were noted even after 9 months (Figure 4).

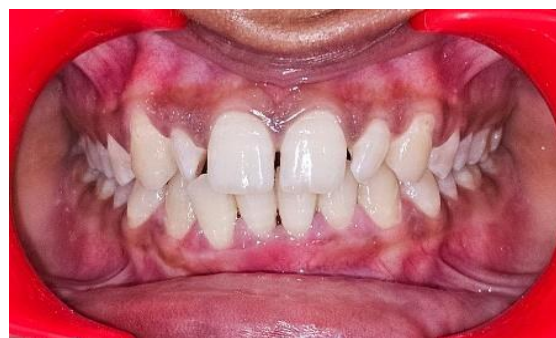

Figure 1

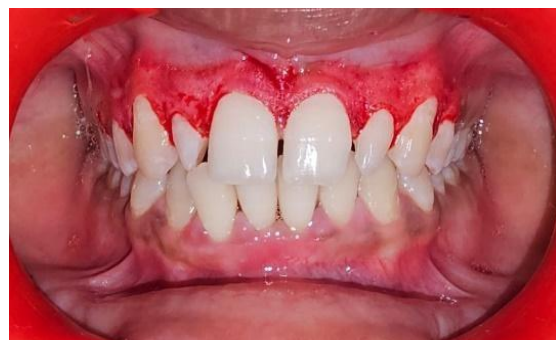

Figure2

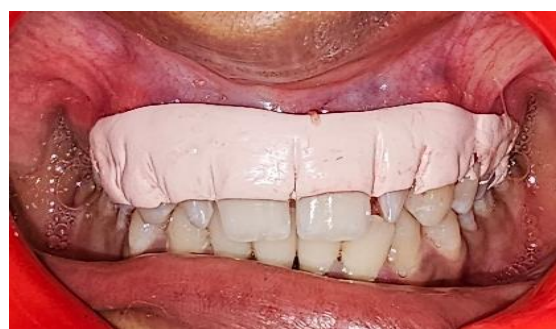

Figure 3

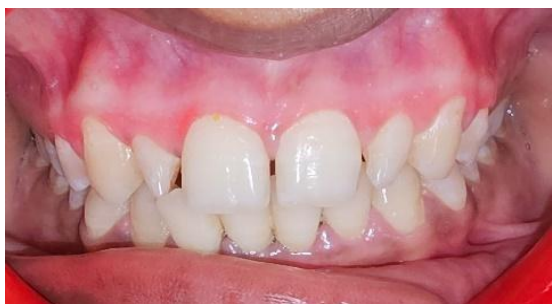

Figure 4

DISCUSSION

Gingival coloration is influenced by four primary factors: vascular supply, epithelial thickness, the extent of epithelial keratinization, and the presence of pigment-producing cells. Melanin pigmentation often results from melanin deposition by active melanocytes, predominantly located in the basal layer of the oral epithelium. Although physiologic pigmentation is largely determined genetically, Dummett proposed that it can also be influenced by mechanical, chemical, and physical stimuli.¹

The main reason individuals seek depigmentation treatment is to enhance esthetics. Various techniques have been used for cosmetic removal of gingival melanin pigmentation, including gingivectomy, gingivectomy with free gingival autograft, acellular dermal matrix allografts, electrosurgery, cryosurgery, abrasion with diamond burs, and laser therapy.³ The choice of method typically depends on clinical experience, cost considerations, and the clinician's personal preference.⁴

Electrosurgery, while effective, requires a higher level of expertise than conventional scalpel surgery. If current is applied too long or repeatedly, it can cause excessive heat and unintended tissue damage. Care must be taken to avoid contact with periosteum, alveolar bone, or vital teeth.⁵

Cryosurgery often results in significant swelling and extensive soft tissue damage. It's challenging to control the depth of freezing, and the optimal freezing time is still uncertain—excessive freezing can lead to increased tissue destruction.⁶ Laser therapy can provide excellent outcomes, but it involves costly and complex equipment.⁷

A free gingival graft may also be used to remove pigmented areas, though it necessitates harvesting tissue from a donor site and may result in color mismatches.⁸ These methods, while effective, are not commonly preferred or widely adopted.

Scalpel surgery is often the method of choice due to its simplicity and the availability of necessary

instruments. Healing from scalpel incisions tends to be quicker than with other techniques. However, the procedure can cause considerable bleeding during and after surgery, necessitating the use of a periodontal dressing for 7 to 10 days.⁹ Despite this, it remains a straightforward and adaptable approach with minimal equipment requirements.

Although initial outcomes from depigmentation surgery are promising, repigmentation is a frequently encountered issue. This recurrence is thought to occur spontaneously and is believed to involve the migration of melanocytes from adjacent pigmented areas, as suggested by the "migration theory."¹⁰ Repigmentation has been reported as early as 24 days post-surgery and as late as 8 years afterward. In the current case, however, no signs of repigmentation were noted after 9 months, and the patient continues to be monitored to evaluate the potential for recurrence.

CONCLUSION

In today's era of heightened smile awareness, the demand for aesthetic dental treatments is steadily increasing. Gingival melanin hyperpigmentation is a frequently observed cosmetic concern. The surgical depigmentation technique utilized in this case proved to be straightforward, cost-effective, and clinically successful in addressing gingival pigmentation, resulting in an improved and visually appealing outcome.

REFERENCES

1. Cicek Y, Ertas U. The normal and pathological pigmentation of oral mucous membrane: a review. *J Contemp Dent pract.* 2003;4(3):76-86.
2. Dummett CO, Barends G. Oromucosal pigmentation: an updated literary review. *J periodontol.* 1971;42(11):726-36.
3. Kasagani SK, Nutalapati R, Mutthineni RB. Esthetic depigmentation of anterior gingiva. A case series. *The New York state Dent J.* 2012;78(3):26-31.
4. Roshna T, Nandakumar K. Anterior esthetic gingival depigmentation and crown lengthening: report of a case. *J Contemp Dent Pract.* 2005;6(3):139-47.
5. Gnanasekhar JD, al-Duwairi YS. Electrosurgery in dentistry. *Quintessence Int.* 1998;29(10):649-54.

6. Yeh CJ. Cryosurgical treatment of melanin-pigmented gingiva. *Oral Surg, Oral Med, Oral Pathol, Oral Radiol, Endod.* 1998;86(6):660-3.
7. Ozbayrak S, Dumlu A, Ercalik-Yalcinkaya S. Treatment of melanin-pigmented gingiva and oral mucosa by CO2 laser. *Oral Surg, Oral Med, Oral Pathol, Oral Radiol, Endod.* 2000;90(1):14-5.
8. Tamizi M, Taheri M. Treatment of severe physiologic gingival pigmentation with free gingival autograft. *Quintessence Int.* 1996;27(8):555-8.
9. Almas K, Sadig W. Surgical treatment of melanin-pigmented gingiva; an esthetic approach. *Indian J Dent Res.* 2002;13(2):70-3.
10. Mokeem, Sameer A. Management of Gingival Hyperpigmentation by Surgical Abrasion : Report of Three Cases. *Saudi Dent J.* 2006;18(3):162-66.

Surgical management of odontogenic keratosis (OKC) - A Case Report

Abstract

Introduction: Facial symmetry refers to a complete match in A significant characteristic feature of OKC (odontogenic keratocyst) is its high recurrence risk as it is a benign but locally aggressive cystic lesion. There is an ongoing debate regarding the most effective method of treatment due to its aggressive behaviour with enucleation — with or without adjunctive therapy still being considered the cornerstone of treatment.

Keywords: OKC; Cystic lesion; Aggressive lesion; Enucleation; Marsupialization.

Dr. Anjani Kumar Jha¹
Dr. Gautam Kumar²
Dr. Tauseef Fazal³
Dr. Priyabrat Panda²
Dr. Barirah Anwar²
Dr. Purushottam Jha²

drgautam091@gmail.com¹

*Department of Oral and Maxillofacial
Surgery.^{1,2,3}
Prof. and H.O.D.¹
Post Graduate Trainee.²
Reader.³*

*Mithila Minority Dental College and Hospital,
Darbhanga, Bihar.^{1,2,3}*

Corresponding Author

Dr. Gautam Kumar

*Mithila Minority Dental College & Hospital,
Darbhanga- 846001,
Bihar, India*

Email: *drgautam091@gmail.com*

INTRODUCTION

Cyst is defined as a pathological cavity or sac within the hard or soft tissues that may contain fluid, semisolid or gaseous material and may or may not be lined by epithelium.¹The World Health Organization (WHO 2022) Defined Odontogenic Keratocyst (OKC) as 'a benign Uni or multicystic intraosseous tumor of odontogenic origin with a characteristic lining of stratified squamous epithelium and has potential for aggressive, infiltrative behaviour.'²

In 1956, Philipsen first identified OKC on the basis of its histopathological characteristics and notable tendency for recurrence. Pindborg and Hansen described the key histopathological characteristics of odontogenic keratocysts. Since then, the classification of OKC has undergone several revisions, with its categorization as either a cyst or a tumor changing across different editions of the WHO Classification. In 2005, the WHO classified OKC as a keratocystic odontogenic tumor (KCOT) due to its neoplastic characteristics. However, in the 4th edition of the Classification of Head and Neck Tumors, published in January 2017, the KCOT was reclassified back to OKC. But in the 5th edition of the WHO classification in 2022, there was no change.

Case Report

A 25-year-old male presented to the Department of Oral and Maxillofacial Surgery with a history of a painless swelling on the lower right side of the cheek, persisting for the past six months. The patient presented with a history of painless swelling in the right lower posterior tooth region, which has been progressively increasing over the last six months. Initially, the patient was asymptomatic, but the swelling gradually grew larger over time. The medical history is non-contributory, with no significant past medical issues. Regarding dental history, the patient underwent extractions of teeth 27, 37, and 47 one year ago. On general physical examination, the patient is moderately built, well-nourished, and exhibits a normal gait. No systemic abnormalities were noted during the examination.



Fig-1: Extra oral clinical

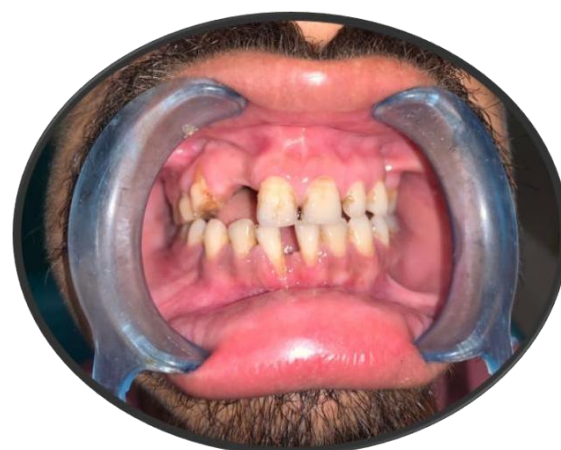

Fig-2: Intraoral view

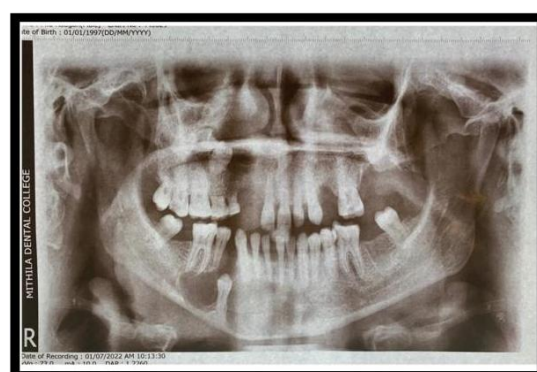

Fig-3: Radiograph showing the radiolucent lesion

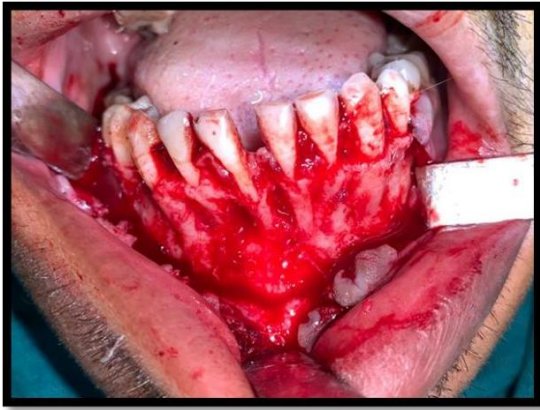

Fig-4: Intra operative view

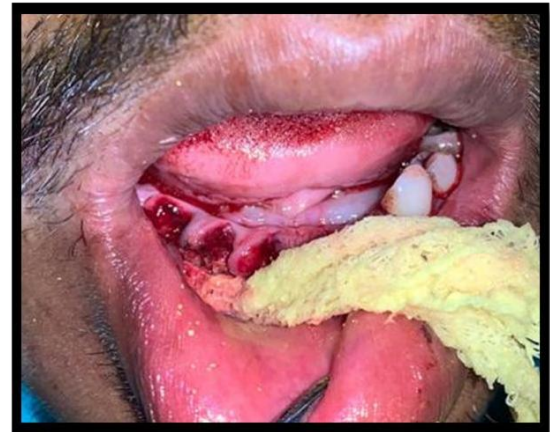

Fig-7: Iodoform dressing given

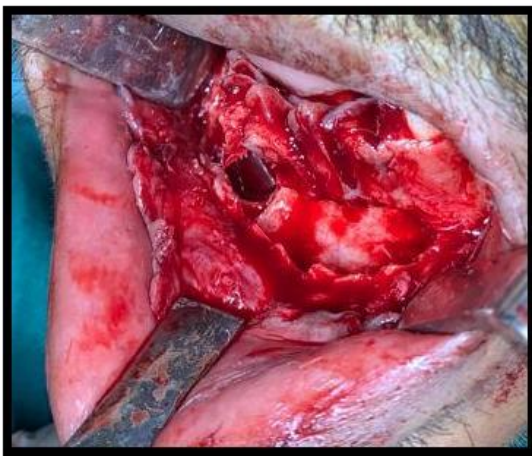

Fig-5: Cystic cavity after enucleation

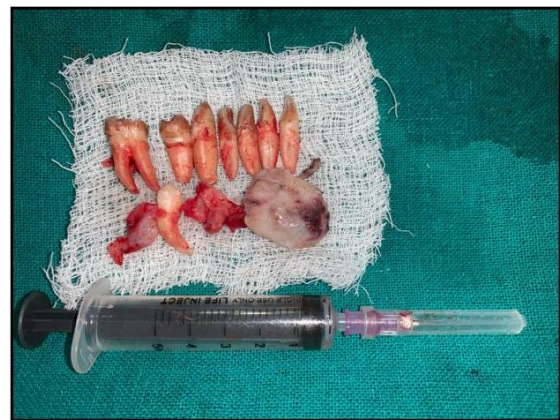

Fig-8: Enucleated tissue along with tooth Sent for biopsy.

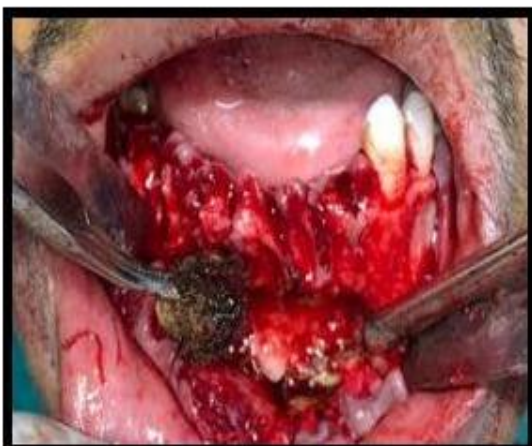

Fig-6: Peripheral ostectomy was done Modified Carnoy's solution application.




Fig-8: Biopsy report

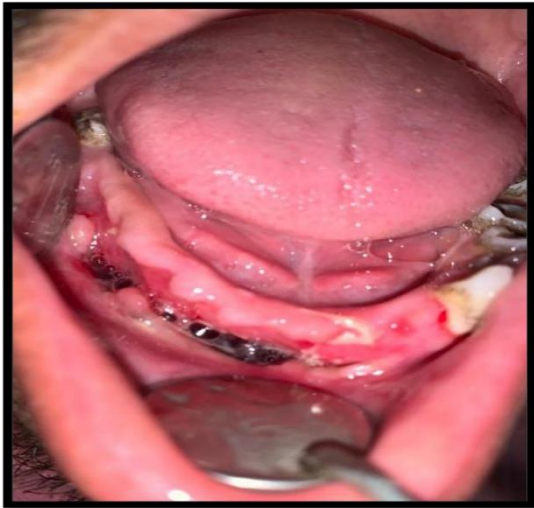

Fig-9: Postoperative picture after 15 days.

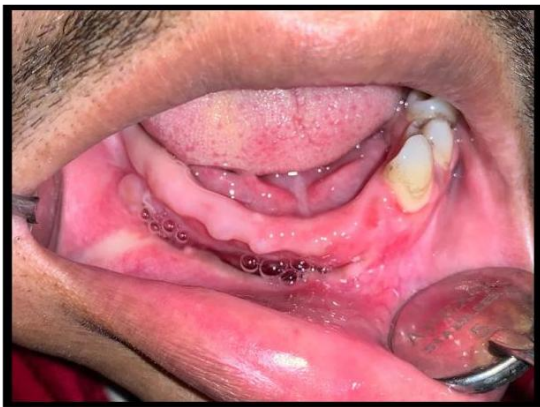

Fig-10: Post operative picture after 1 month

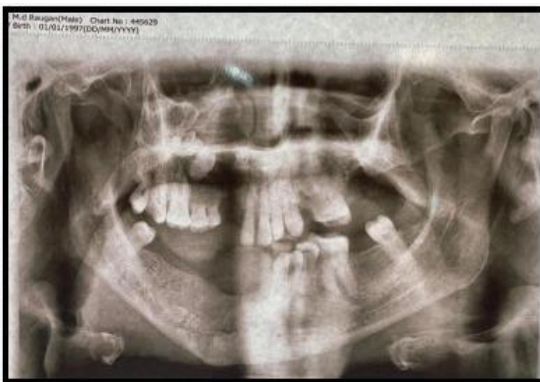

Fig-11: One year follow up radiograph and well-defined bone formation seen in (OPG) radiograph

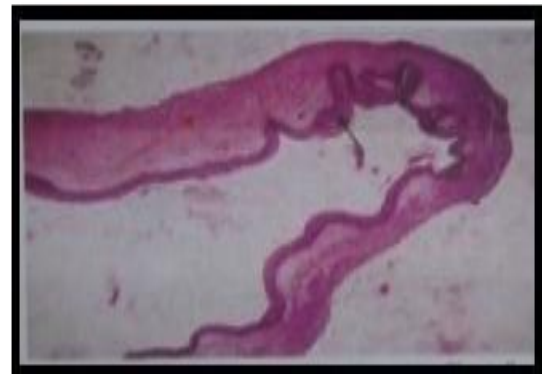

Fig-12: Histopathological view.

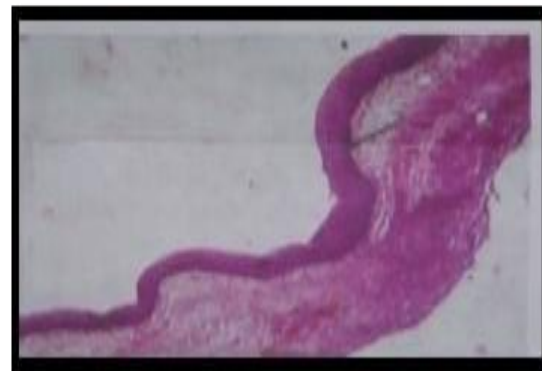

Fig-13: Histopathological view.

Excisional biopsy was suggestive of the lesion being an odontogenic keratocyst. Tissue bits show cyst wall lined by stratified squamous epithelium with Para keratinisation exhibiting hyperplasia and focal ulceration at place the sub-epithelium is infiltrate moderate to dense mixed infiltrate comprising of lymphocytes, plasma cells, histocytes, neutrophil along with area of haemorrhage, Fibrosis and congested blood vessels. The H & E-stained histopathological section shows cystic lumen lined by 6-8 layer parakeratinised stratified squamous epithelium having tall columnar basal cell with palisading nuclei and flat epithelial connective tissue interference underlying cystic wall is fibro collagenous and show patchy chronic inflammatory infiltrate.

Discussion

In 2005, the World Health Organization (WHO) reclassified the odontogenic keratocyst (OKC) as a keratocystic odontogenic tumor (KCOT) due to its neoplastic characteristics. This reclassification reflects the lesion's nature as a benign, Uni- or

multicystic, intraosseous tumor of odontogenic origin, with a distinctive lining of parakeratinised stratified squamous epithelium and the potential for aggressive, infiltrative behaviour.² The treatment of OKC requires careful consideration of various factors, including the patient's age, the cyst's size and location, soft tissue involvement, and the history of previous treatments.³ The primary goal is to reduce the recurrence risk while minimizing morbidity. Surgical intervention options include complete or partial resection, which has the lowest recurrence rates (less than 2%) but can be associated with significant morbidity. To reduce recurrence further, adjuvant therapies, such as chemical cauterization with Carnoy's solution or peripheral osteotomy, may be applied after enucleation.⁴ Brannon (1976) proposed that recurrence mechanisms include incomplete removal of the cyst lining, presence of satellite or daughter cysts, and the development of new OKC in adjacent areas, with recurrence rates ranging from 2.5% to 62%. Treatment modalities such as decompression, marsupialization, and enucleation (either alone or combined with various adjuncts like primary closure, packing, chemical agents, or cryosurgery) are commonly employed.⁶ Studies have shown that enucleation combined with adjunctive measures, such as Carnoy's solution, is associated with minimal recurrence rates. For example, a study by Alchalabi et al. (2017) found that the complications and morbidity associated with Carnoy's solution were less frequent and less severe compared to resection, with a recurrence rate of 0%. Additionally, Dias et al. (2016) reported that the combination of enucleation and adjunctive therapies results in lower recurrence rates compared to enucleation alone. In cases where enucleation creates a large surgical defect, it is often necessary to pack the cavity with aseptic dressing material to promote healing and prevent infection, as primary closure can lead to complications due to the substantial dead space created (Vijay Kumar, 2015).

CONCLUSION

Our paper highlights that a proper diagnosis should always be determined before initiating any management. Initial decompression followed by enucleation, combined with adjunctive therapies, helps reduce the risk of disease recurrence. Although various treatment modalities for odontogenic keratocysts have been studied, identifying a universally accepted management strategy continues to be a matter of debate.

REFERENCES

1. A text book of oral pathology – Shafer's
2. Valdivia AD, Ramos-Ibarra ML, Franco-Barrera MJ, et al. What is currently known about odontogenic keratocyst. *Oral Health Prev Dent* 2022; 20:321–330.
3. 2. Li TJ. The odontogenic keratocyst: a cyst, or a cystic neoplasm? *J Dent Res* 2011; 90:133–142
4. Motaleb L, Zakai D, Stocker J, 14-year study of the management of the Odontogenic Keratocyst. Are adjunctive therapies all they are cut out to be? *British Journal of Oral and amp; Maxillofacial Surgery* (2021),
5. Deepak Passi, Deepika Singhal, Mahinder Singhet al. 2017. "Odontogenic Keratocyst (OKC) or Keratocystic Odontogenic Tumor (KCOT) journey of OKC from cyst to tumor to cyst again : Comprehensive review with recent updates on who classification (2017) *International Journal of Current Research*, 9, (07), 54080-54086.
6. Henriette L. Moellmann¹ · Aida Parviz¹ Marcia Goldmann- Kirn² Madiha Rana³, Majeed Rana¹Received: 17 July 2022 / Accepted: 28 April 2023 / Published online: 21 June 2023© The Author(s) 2023
7. James R. Hupp, Edward Ellis III, Myron R. Tucker: *Contemporary Oral and maxillofacial surgery*. 5th Edition.
8. Marx & Stern: *Oral and maxillofacial pathology*.
9. *Surgical pathology*. Fonseca.

Denture Rebasing: A Case Report – Giving Your Denture A Second Chance

Abstract

Introduction: According to Sangiuolo, relining and rebasing are the two primary techniques for changing the denture base. Rebasing is defined as "a process of refitting a denture by replacing the denture base material while maintaining the same prosthetic teeth." The major goals are to maintain the original jaw relations and restore proper denture base adaptation to the bearing area. When physiological or pathological resorption causes an immediate or late static prosthetic instability, this technique is primarily indicated. This clinical report attempts to cover the common complete denture rebasing procedure along with a simple description of clinical and laboratory steps that can any practitioner follow to succeed the prostheses base replacement.

Keywords: Complete denture, Rebasing technique, Prosthetic instability, General complaints, Resorbed ridge, Functional impression

Dr. Abhishek Ghosh¹
Dr. Suvajit Adak²
Dr. Sudheer Arunachalam³
Dr. Priya⁴
Dr. Abhilash Srivastava⁵

suvaajitadak999@gmail.com¹

*Department of public health dentistry¹,
Department of prosthodontics and crown &
bridge.^{2,3,4,5,6}
Professor.¹
Post Graduate Trainee.^{2,5}
Principal and H.O.D.³
Assistant Professor⁴*

*Mithila Minority Dental College and Hospital,
Darbhanga, Bihar.^{1,2,3,4,5,6}*

Corresponding Author

Dr. Suvajit Adak

*Mithila Minority Dental College & Hospital,
Darbhanga- 846001,
Bihar, India*

Email: *suvaajitadak999@gmail.com*

INTRODUCTION

Although most edentulous patients are satisfied with their new complete dentures, up to 30% may experience problems with the denture.¹ They still experience adaptation difficulties include unsatisfactory appearance, pain from lack of retention and stability, altered speech, food accumulation under the denture, and difficulty chewing.² Complaints can negatively impact a person's quality of life and require further consultation to resolve.³ To address these issues, rebasing is a recommended clinical procedure in certain situations.⁴

Sangiulio suggests that total repair involves redoing the base of the prosthesis with heat-polymerized acrylic resin. This can be done directly or indirectly, and requires laboratory intervention. This technique involves replacing the base material of an existing denture without changing the occlusal relations of the teeth. This restores stability and retention and re-establishes the denture's proper relationship with the basal tissue, without the need for a new denture.²

This article aims to present through a series of illustrations, leading us to re-use the prosthetic base for total rebasing and to high its added value in the practitioner daily practice. It also illustrates the different clinical and laboratory stages of this therapeutic.

CASE REPORT

A 67-year-old male patient with no medical history presented to the department of Prosthodontics and Crown & Bridge at Mithila Minority Dental College and Hospital, Darbhanga with a chief complaint of loosening of upper denture. The loose denture was delivered less than two years ago as part of the prosthodontic exercise. His previous records stated that the dentures were acceptable on delivery. (Figure 1)

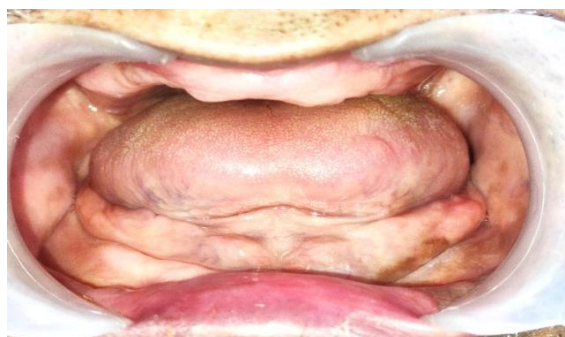

Fig-1: Pre operative intra-oral photograph

When the upper denture was evaluated, it showed acceptable stability but no retention. Due to bilateral border deficiencies surrounding the distobuccal area, the extension was acceptable but not optimal.

There was a gap in the posterior palatal seal. The phonetics and physiologic rest position techniques confirmed that the current vertical jaw relation was satisfactory. There was no uneven occlusal contact, and the centric occlusion was consistent with centric relation. Overall, the patient was pleased with the aesthetics. No pathologic alterations were found upon examination of the denture bearing region.

After being taken out, the dentures were examined. The tissue surface of the upper denture's palatal vault was a bit "too smooth," with features that didn't blend in with his natural anatomy. When questioned further, he admitted that he had frequently used sandpaper to make adjustments to the upper denture's borders and tissue surface because they were uncomfortable. Surprisingly, he made all of these changes by himself. The mandibular denture is completely fine with proper retention and stability. (Figure 2 & 3)

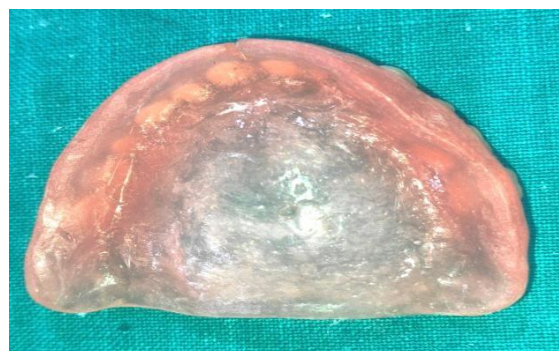


Fig-2: Self-adjusted maxillary denture

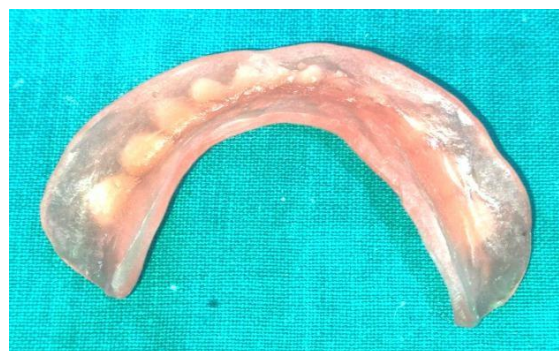

Fig-3: Mandibular denture

The patient accepted our suggestion to rebase the upper denture. With the exception of the posterior palatal seal region, the denture's border was uniformly reduced by 2 mm, and the undercut on the intaglio surface was relieved. **(Figure 4)**

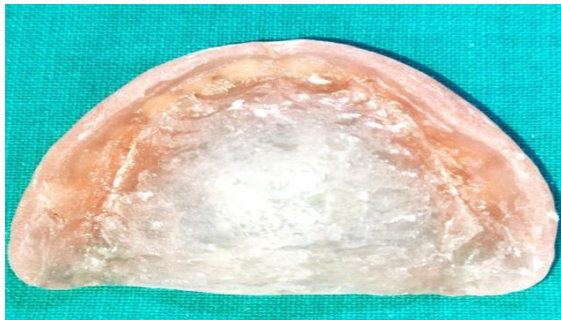

Fig-4: overall reduction of 2mm peripherally and from intaglio surface

Green stick impression compound was then used for border moulding, and relief holes were made on the palatal region. During the final impression using zinc oxide eugenol (ZOE) paste, the denture was seated using the pre-existing centric occlusion. **(Figure 5 & 6)**

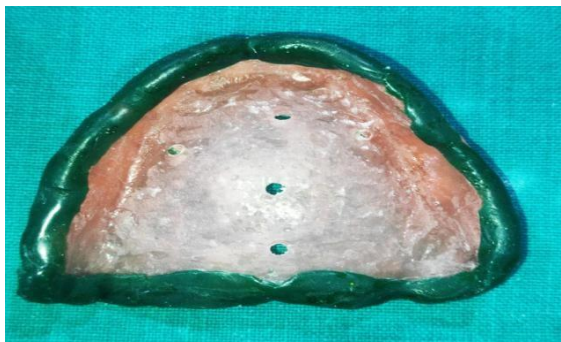


Fig-5: Border moulding of maxillary denture

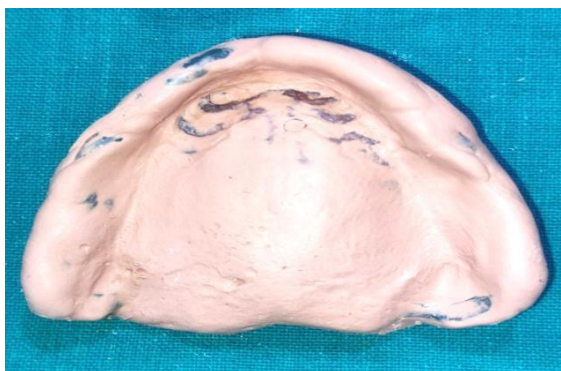


Fig-6: Final impression by using ZOE paste

To create a master cast, dental stone was poured after beading and boxing were completed. **(Figure 7)**




Fig-7: Beading and boxing

Mounted on the articulator's upper member, the master cast with the denture in place was indexed. Petroleum jelly was applied to the palate and teeth's occlusal surfaces once the mounted plaster had solidified. A new mixture of dental plaster was placed to the articulator's lower member and sealed, ensuring that the teeth's occlusal surfaces only emerged 2 mm into the plaster. **(Figure 8)** After allowing the second plaster mixture to solidify, the upper and lower members were separated. All impression remnants were then eliminated from the denture after it had been carefully taken out of the master cast.

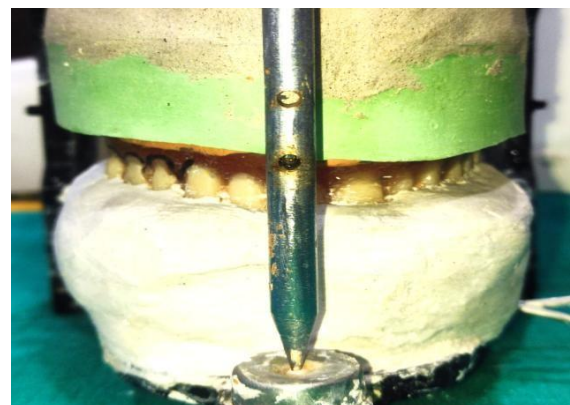


Fig-8: occlusal surface of the maxillary denture teeth making indentations on the plaster on the lower member

The majority of the denture base was cut away, leaving only a thin horseshoe-shaped piece of old denture acrylic resin that held the acrylic teeth together in a single block. The teeth block was

seated over the indentations on the lower member. **(Figure 9)**

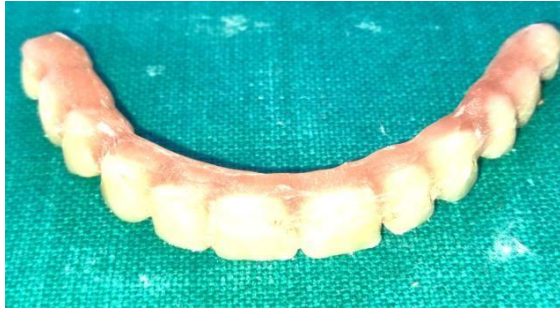

Fig-9: narrow horseshoe of acrylic resin holding the arch of teeth

After the appropriate thickness and contour were achieved by waxing the area between the teeth and the master cast, denture processing was completed using heat-cured acrylic resin in the traditional manner. **(Figure 10)**

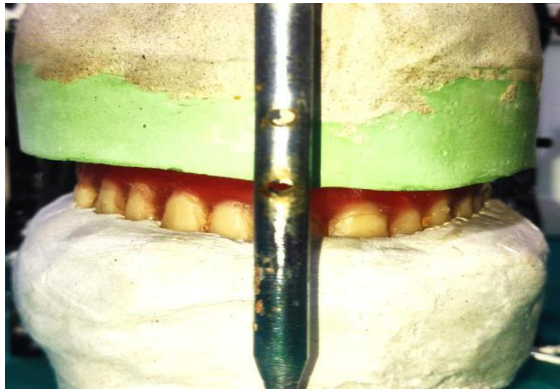

Fig-10: The denture teeth are waxed to the proper thickness and contour to the cast

Lab remounting of the polymerized denture was done to correct occlusal errors. The denture was then polished, finished, and trimmed. **(Figure 11)**

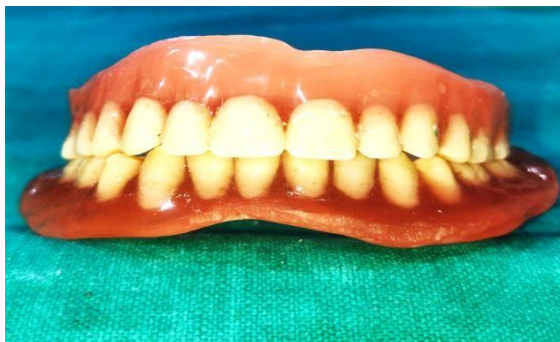

Fig-11: Dentures after finishing and polishing

The patient was satisfied with the result and the denture's retention was noticeably enhanced upon delivery. At the subsequent follow-up, minor occlusal corrections were made, and patient motivation and education were reinforced. **(Figure 12,13,14)**

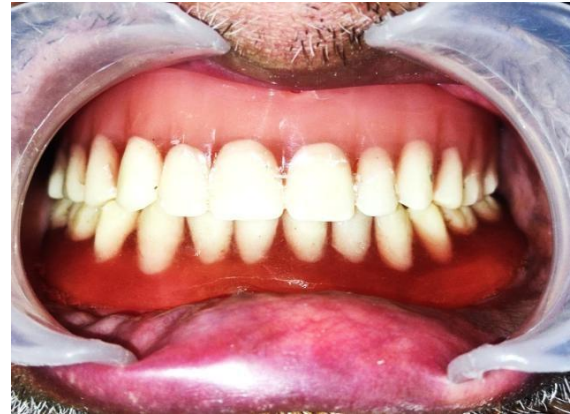

Fig-12: Intra-oral photograph




Fig-13: Pre-op photograph



Fig-14: Post-op photograph

DISCUSSION

Rebasing may be a very cost-effective solution in certain situations involving porous, discoloured, or contaminated denture bases. It may also be an option for elderly patients, people with mental impairments, and chronically ill patients with conditions like non-equilibrated diabetes that causes ongoing resorption of the residual alveolar ridges who cannot afford the expense or the numerous, prolonged appointments needed to construct a new denture. This process improves the prosthesis' stability and preserves the remaining bone while also improving comfort (better speech, chewing, and general attitude).^{5,6,7} But what is the real efficiency of this denture impression procedure?^{8,9} When the modified denture is ultimately subjected to a standard poly-methyl methacrylate polymerized denture, it experiences the same margin of error (denture base thickness, inter-occlusal rest space affecting the DV, and occlusal variation) as the original consultation because of polymerization shrinkage.¹⁰

Accurate functional impressions and other properly executed clinical and laboratory procedures guarantee increased stability and retention.¹¹ In fact, the preferred method for many authors is still too rebase with a functional ordinary final impression using the zinc oxide-eugenol paste for the intrados surfacing and the Kerr paste to record the intrados and Kerr paste's peripheral limits.²

In recent years, some authors have recommended using specific elastomers for border moulding, either by themselves or in conjunction with Kerr paste.¹² The primary benefit of this method is that it preserves the physiological free play of paraprosthetic organs while recording the highest and widest prosthetic edges. To address the various anatomical shapes of the support surfaces and the patient's muscle power recording, other authors suggest a surfacing that uses materials with varying viscosities.¹³

Rebasing can actually provide a maximum base extension and a larger area of close contact between the mucosa membrane and the denture base in these situations by using an accurate impression technique, which significantly improves the stability of the denture and the support of the basal seat. A tissue preparation before making the impression is essential to the success of this procedure and may require multiple sessions, particularly in certain cases where the tissue is severely affected. This is in addition to having excellent knowledge and perfect control of the clinical steps. To achieve a clinically healthy soft tissue state prior to making an impression, a tissue

conditioner treatment is established and renewed weekly. In the event of an ill-fitting denture, it is also necessary to aid tissue recovery by removing isolated pressure spots, which will modify the transmission of masticatory forces to the supporting mucosa. Pressure points in the pink zone ought to be released. In the event of epulis fissuratum or traumatic vestibular mucosa lesions, overextended borders are also lessened. Before rebasing, the excessively hypertrophic tissue must also be surgically managed. The denture can then be used as a surgical splint.²

Some recommendations are made to speed up the healing of the tissue. For instance, the patient should keep the old denture out of his mouth as much as possible, preferably at night and especially before taking the final impression, to ensure tissue rest.²

In order to promote blood flow and healing, a soft tissue massage is also advised. To summarise, rebasing is a compromise agreed upon with the patient; it avoids the need for more frequent and costly denture renewals, and the patient may adjust to the rebased dentures more quickly because the facial features and appearance are replicated.¹⁴

Although some dentists advise relining, others prefer to reprocess the old denture on a cast from a fresh impression, and still others advise creating new dentures when the residual ridges have resorbed extensively with significant loss of vertical height or when establishing proper occlusion is challenging.¹⁵

Conventional complete denture fabrication is now part of the expanded field of removable prosthodontics thanks to computer-aided design and manufacturing (CAD/CAM) technology. Even so, the number of reports on computer-engineered complete dentures (CECDs) keeps rising.^{16,17,18,19,20}

CONCLUSION

As one of the most clinical stages of denture fabrication, a routine yearly visit for control or adjustment appointments is crucial to ensuring patient care and maintaining oral health. Therefore, checkups are important to identify any variations in the various parameters or issues that can be resolved with minor adjustments if necessary.² Otherwise, rather than just a genuine design flaw or a tissue issue, it is reasonable to consider some proper (individual) patient factors, such as age, gender, medical, or psychological status, as impeding the success of treatment.²

REFERENCES

- Shah FK, Gebreel A, hamed Elshokouki A, Habib AA, Porwal A. Comparison of immediate complete denture, tooth and implant-supported overdenture on vertical dimension and muscle activity. *The Journal of Advanced Prosthodontics*. 2012 May 1;4(2):61-71.
- Jemli S. Rebasing as a Problem-Solving in Complete Dentures. *Saudi J Oral Dent Res*. 2021;6(6):227-33.
- Roumanas ED. The social solution—denture esthetics, phonetics, and function. *Journal of Prosthodontics: Implant, Esthetic and Reconstructive Dentistry*. 2009 Feb;18(2):112-5.
- Sadr K, Mahboob F, Rikhtegar E. Frequency of traumatic ulcerations and post-insertion adjustment recall visits in complete denture patients in an Iranian faculty of dentistry. *Journal of dental research, dental clinics, dental prospects*. 2011 Jun 14;5(2):46.
- Corsalini M, Rapone B, Grassi FR, Di Venere D. A study on oral rehabilitation in stroke patients: analysis of a group of 33 patients. *Gerodontology*. 2010 Sep;27(3):178-82.
- Verma M, Gupta A. Post insertion complaints in complete dentures—a never ending saga. *Journal of Academy of Dental Education*. 2014 Jun 30;1(1):1-8.
- McCord JF, Grant AA. Identification of complete denture problems: a summary. *British dental journal*. 2000 Aug;189(3):128-34.
- Koblitz FF, Smith RA, Wolfe HE. Fluid denture resin processing in a rigid mold. *The Journal of Prosthetic Dentistry*. 1973 Sep 1;30(3):339-46.
- Kranjčić J, Kostelić Stunić M, Celebić A, Komar D, Mehulić K, Vojvodić D. Denture relining as an indicator of residual ridge resorption. *Med Glas (Zenica)*. 2013 Feb 1;10(1):126-32.
- Mohammed S, Alla RK, Devarhubli A, Shakeel SK. Changes in Vertical Dimension of Complete Dentures due to Rebasing with Different Techniques. *World Journal of Dentistry*. 2014 Dec 1;4(2):96-9.
- Yadav B, Jayna M, Yadav H, Suri S, Phogat S, Madan R. Comparison of different final impression techniques for management of resorbed mandibular ridge: a case report. *Case reports in dentistry*. 2014;2014(1):253731.
- Naser B, Postaire M. (1991). Élastomères et joint périphérique en prothèse complète maxillaire, *Cah Prothèse* ; 75 : 47-55
- Devaki VN, Manonmani P, Balu K, Aravind RJ. Clinical management of highly resorbed mandibular ridge without fibrous tissue. *Journal of Pharmacy and Bioallied Sciences*. 2012 Aug 1;4(Suppl 2):S149-52.
- Salih HA, Al-Jmoor CA, Abdulazeez JR. Clinical assessment of common complaints among complete dentures wearers, in relation to, age and gender. *Int J Dev Res*. 2016;6(2):6683-7.
- Christensen FT. Relining techniques for complete dentures. *The Journal of Prosthetic Dentistry*. 1971 Oct 1;26(4):373-81.
- Kattadiyil MT, AlHelal A. An update on computer-engineered complete dentures: A systematic review on clinical outcomes. *The Journal of prosthetic dentistry*. 2017 Apr 1;117(4):478-85.
- Abdelnabi MH, Swelem AA. Digital technology in complete denture prosthodontics: a review of literature. *Egyptian Dental Journal*. 2017 Jul 1;63(3-July (Fixed Prosthodontics, Dental Materials, Conservative Dentistry & Endodontics)):2871-85.
- Bidra AS, Taylor TD, Agar JR. Computer-aided technology for fabricating complete dentures: systematic review of historical background, current status, and future perspectives. *The Journal of prosthetic dentistry*. 2013 Jun 1;109(6):361-6.
- Janeva N, Kovacevska G, Janev E. Complete dentures fabricated with CAD/CAM technology and a traditional clinical recording method. *Open access Macedonian journal of medical sciences*. 2017 Oct 6;5(6):785.
- Alqarni H, AlHelal A, Kattadiyil MT. Computer-engineered complete denture fabrication with conventional clinical steps: A technique to overcome protocol limitations. *The Journal of Prosthetic Dentistry*. 2019 Nov 1;122(5):430-4.